Update and Controversies in the Surgical Management of Oral and Maxillofacial Pathology

Eric R. Carlson, DMD, MD, EdM, FACS

Senior Associate Dean for Faculty Development and Affairs

Professor of Surgery

University of Toledo College of Medicine and Life Sciences

Toledo, Ohio

eric.carlson2@utoledo.edu

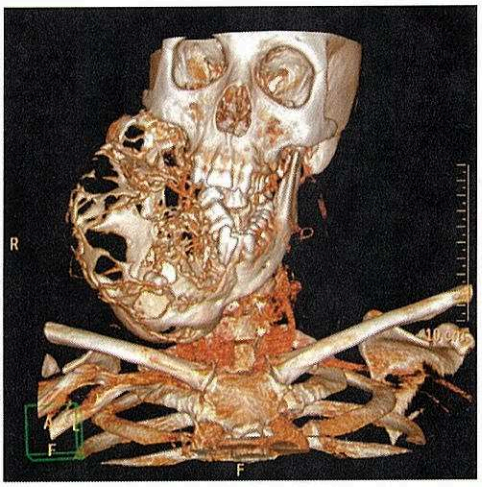

Update and Controversies in the Surgical Management

of Oral and Maxillofacial Pathology

Synopsis

The surgical management of oral/head and neck pathology represents a formidable discipline in the specialty of oral and maxillofacial surgery. Such pathology is diagnostically diverse and variable in its biologic behavior, ranging from indolent non-neoplastic benign processes to locally aggressive benign tumors to overly aggressive and fast-growing malignancies that are capable of distant spread. An appreciation for the biologic behavior of benign and malignant tumors comes to rest on our knowledge of their doubling times, their involvement of surrounding anatomic barriers, and their potential for metastatic spread, all of which assist in the development of the timing and execution of ablative surgery. The seasoned tumor surgeon is also capable of diagnosing and managing complications related to benign and malignant processes of the oral/head and neck region.

Osteonecrosis of the jaws is not a new diagnostic classification in oral and maxillofacial surgery or oral and maxillofacial pathology. Nonetheless, our specialty began learning of the association of oral and intravenous bisphosphonate medications and osteonecrosis of the jaws in 2003. Thereafter, we began to appreciate the association of RANKL inhibiters in the diagnosis of osteonecrosis of the jaws. Therein, the nomenclature of this process changed from bisphosphonate related osteonecrosis of the jaws (BRONJ) to medication related osteonecrosis of the jaws (MRONJ). Since that time, the main controversial elements associated with these cases include the pathophysiology and cause of MRONJ as well as its proper treatment. While the medications themselves were once assigned primary etiology in the development of osteonecrosis, many scholars have cited the presence of osteonecrosis of the jaws in similarly physiologically compromised individuals, including those with cancer with or without metastatic disease,

diabetes mellitus, alcoholism, and other diagnoses. A critical analysis of patients with MRONJ identifies numerous risk factors responsible for an aggressive form of osteomyelitis that also exist in patients not taking bisphosphonate medications.

Odontogenic cysts and tumors are time honored and formidable diagnoses of interest in oral and maxillofacial surgery practice. These processes range from indolent and serendipitously discovered cysts to large and disfiguring malignant processes capable of death of the patient. Therein, unilocular and multilocular radiolucencies of the jaws conjure a diverse and comprehensive differential diagnosis that must be mastered in oral and maxillofacial surgery training programs and continually modified throughout subsequent practice.

It is the purpose of this presentation to review commonly diagnosed pathologic processes of the oral cavity and jaws, specifically MRONJ and odontogenic cysts and tumors. Evidence-based methods in diagnosis and management will be reviewed with the intention of emphasizing techniques to cure the pathologic process while also maintaining the patient's facial form and functional capacity.

American Association of Oral and Maxillofacial Surgeons' Position Paper on Medication-Related Osteonecrosis of the Jaws—2022 Update

Salvatore L. Ruggiero, DMD, MD, [*] *Thomas B. Dodson, DMD, MPH,* [†] *Tara Aghaloo, DDS, MD, PhD,* [‡] *Eric R. Carlson, DMD, MD, EdM,* [§] *Brent B. Ward, DDS, MD,* [‖] *and Deepak Kademani, DMD, MD* [¶]

Strategies for management of patients with, or at risk for, medication-related osteonecrosis of the jaws (MRONJ) - formerly referred to as bisphosphonate-related osteonecrosis of the jaws (BRONJ)—were set forth in the American Association of Oral and Maxillofacial Surgeons (AAOMS) position papers in 2007, 2009 and 2014. The position papers were developed by a committee appointed by the AAOMS Board of Trustees and comprising clinicians with extensive experience in caring for these patients, as well as clinical and basic science researchers. The knowledge base and experience in addressing MRONJ continues to evolve and expand, necessitating modifications and refinements to the previous position papers. Three members of the AAOMS Committee on Oral, Head, and Neck Oncologic and Reconstructive Surgery (COHNORS) and three authors of the 2014 position paper were appointed to serve as a working group to analyze the current literature and revise the guidance as indicated to reflect current knowledge in this field. This update contains revisions to diagnosis and management strategies and highlights the current research status. AAOMS maintains that it is vitally important for this information to be disseminated to other relevant healthcare professionals and organizations.

© *2022 American Association of Oral and Maxillofacial Surgeons*

J Oral Maxillofac Surg 80:920-943, 2022

Medications prescribed for dental and medical conditions have potential side effects that warrant a risk-benefit discussion. Where therapeutic margins are wide and complications are readily corrected, decisions are implemented in a straightforward fashion. Where therapeutic margins are wide but

[*]Clinical Professor, Division of Oral and Maxillofacial Surgery, Stony Brook School of Dental Medicine, Hofstra North Shore-LIJ School of Medicine, New York Center for Orthognathic and Maxillofacial Surgery, Lake Success, NY.

†Professor and Chair, University of Washington School of Dentistry, Department of Oral and Maxillofacial Surgery, Seattle, Wash.

‡Professor, Oral and Maxillofacial Surgery, UCLA School of Dentistry, Los Angeles, Calif.

§Professor and Kelly L. Krahwinkel Endowed Chairman, Department of Oral and Maxillofacial Surgery, University of Tennessee Graduate School of Medicine, Knoxville, Tenn.

‖Chalmers J Lyons Professor of Oral and Maxillofacial Surgery, Associate Professor of Dentistry, Chair of the Department of Oral and Maxillofacial Surgery/ Hospital Dentistry in the School of Dentistry and Associate Professor of Surgery for the Medical School, University of Michigan Hospital, Ann Arbor, Mich.

¶Chief of Staff North Memorial Health, Fellowship Director, Oral/Head and Neck Oncologic and Reconstructive Surgery Attending Surgeon, North Memorial Health and the University of Minnesota. Private practice, Minnesota Oral and Facial Surgery and Minnesota Head and Neck Surgery, Minneapolis, Minn.

Conflict of Interest Disclosures: Dr Ruggiero serves as a consultant for Amgen. Dr Dodson serves as a consultant for AAOMS. Dr Aghaloo has received research grants from OMS Foundation and Amgen. Dr Carlson receives book royalties from Wiley Blackwell, Quintessence, and Elsevier. Dr Ward serves as a consultant for AAOMS, AACMES, and OsteoScience. Dr Kademani serves as a consultant for AAOMS and is the director of ABOMS.

Address correspondence and reprint requests to Dr Ruggiero: Clinical Professor, Division of Oral and Maxillofacial Surgery, Stony Brook School of Dental Medicine, Hofstra North Shore-LIJ School of Medicine, New York Center for Orthognathic and Maxillofacial Surgery, Lake Success, NY; e-mail: sruggie@optonline.net

Received December 29 2021

Accepted February 15 2022

© 2022 American Association of Oral and Maxillofacial Surgeons

0278-2391/22/00148-3

https://doi.org/10.1016/j.joms.2022.02.008

complications are significant, deciding to proceed with pharmacologic treatment becomes more challenging. In most cases of MRONJ, local therapies can be successful. The fact that more complex treatment is required for a few patients should not impact decision-making for all other patients with osteonecrosis of the jaws. The medications associated with MRONJ have proved to be safe and effective in clinical trials and postmarketing analyses for most patients and should continue as a mainstay therapy when indicated. Communicating the risks of MRONJ to patients and providers is critical to ensure appropriate medical management for the primary disease.

Undoubtedly, risk profiles may change as new medications come to market. In addition, our understanding of disease pathophysiology, risk modifiers, and treatment strategies will continue to evolve. It is of the utmost importance that clinicians base their patient treatment decisions on currently available scientific evidence.

Strategies for management of patients at risk for or with MRONJ were set forth in American Association of Oral and Maxillofacial Surgeons (AAOMS) Position Papers in 2007,[1] 2009,[2] and 2014.[3] These position papers were developed by a committee appointed by the AAOMS Board of Trustees and comprised of clinicians with extensive experience in caring for these patients, as well as clinical and basic science researchers. The knowledge base and experience in addressing MRONJ continues to evolve and expand, necessitating modifications and refinements to the previously published position papers. A working group comprised of three members of the AAOMS Committee on Oral, Head, and Neck Oncologic and Reconstructive Surgery (COHNORS) and three authors of the 2014 paper convened remotely in the fall of 2020 to appraise the current literature and revise the guidelines as indicated to reflect the current knowledge in this field. This update contains revisions to the pathogenesis and management strategies and highlights the current research status. AAOMS maintains it is vitally important for this information to be disseminated to other relevant healthcare professionals and organizations.

Purpose

The purpose of this position paper is to provide updates regarding:

1. Risk estimates for developing MRONJ.
2. Comparisons of the risks and benefits of medications related to osteonecrosis of the jaw in order to facilitate medical decision-making for the treating physician, dentist, dental specialist, and patient with the establishment of algorithms.
3. Guidance to clinicians regarding:
   a. The differential diagnosis of MRONJ in patients with a history of exposure to antiresorptive medications.
   b. MRONJ prevention measures and management strategies for patients with MRONJ based on the disease stage.

Medications

Bisphosphonates (BPs) are antiresorptive medications that are effective in managing cancer-related conditions, including hypercalcemia of malignancy, spinal cord compression, and pathologic fractures (skeletal-related events [SREs]) associated with bone metastases in the context of solid tumors (such as breast, prostate, and lung cancers) and multiple myeloma.[4-13] While the potential for BPs to improve cancer-specific survival remains controversial, these medications have had a significant positive effect on the quality of life for patients with advanced cancer involving the skeleton and reducing or preventing skeletal-related events.

Bisphosphonates also are used for the prevention of osteoporosis-related fractures (fragility fractures) in patients with osteoporosis and osteopenia.[14-16] BPs administered orally–including alendronate (Fosamax®), risedronate (Actonel®) or parenterally (zoledronic acid [Reclast®]), and ibandronate (Boniva®)—can result in a significant reduction in vertebral and nonvertebral fractures for patients with osteoporosis.[17-20]

Bisphosphonate therapy also is indicated for other metabolic bone diseases such as Paget's disease of bone and osteogenesis imperfecta.[21-23] However, clinical trials have not demonstrated the efficacy of bisphosphonate therapy in the management of fibrous dysplasia.[24]

Denosumab (DMB), a receptor activator of nuclear factor kappa-B ligand (RANK-L), is an antiresorptive agent that exists as a fully humanized antibody against RANK ligand and inhibits osteoclast function and associated bone resorption. When denosumab (Prolia®) is administered subcutaneously every 6 months, there is a significant reduction in the risk of vertebral, nonvertebral, and hip fractures in osteoporotic patients.[25-28] Denosumab (Xgeva®) also is effective in reducing SREs related to metastatic bone disease from solid tumors when administered monthly.[29-31]

RANK ligand inhibitors also have proven efficacy in the treatment of giant cell tumors of bone and fibrous dysplasia.[32-36] In contrast to BPs, RANK-L inhibitors do not bind to bone, and their effects on bone remodeling are mostly diminished within 6 months of treatment cessation.

Romosozumab is a new monoclonal antibody used for fracture prevention in osteoporotic women. Romosozumab, administered subcutaneously, works via the Wnt pathway by binding to and inhibiting sclerostin, resulting in increased bone formation and decreased bone resorption.[37]

MRONJ Case Definition

MRONJ should be distinguished from other forms of osteonecrosis (ONJ) conditions and identified by history and clinical exam. The clinical criteria required to establish a diagnosis of MRONJ have remained unchanged from the previous position paper.[3]

The case definition of MRONJ includes all the following elements:

1. Current or previous treatment with antiresorptive therapy alone or in combination with immune modulators or antiangiogenic medications.
2. Exposed bone or bone that can be probed through an intraoral or extraoral fistula(e) in the maxillofacial region that has persisted for more than 8 weeks.
3. No history of radiation therapy to the jaws or metastatic disease to the jaws.

Staging

A staging system for MRONJ was introduced in the 2009 AAOMS position paper and then modified in the 2014 position paper to characterize more accurately all aspects of the clinical presentation of MRONJ. Since these modifications, the AAOMS staging system has continued to be a straightforward and relevant system to properly stratify these patients. It has been adopted by several professional societies and research organizations. The staging system facilitates the creation of rational treatment guidelines and guides data collection to assess the prognosis and outcomes for MRONJ patients. While AAOMS recognizes that different classification systems are being used by other organizations,[38] the Association considers the AAOMS system to be a useful and widely implemented assessment tool guiding clinicians involved in the care of MRONJ patients. AAOMS remains concerned that overemphasizing variable radiographic features often attributed to MRONJ may overestimate the true disease frequency by including false positives in the numerator (eg, cases with radiographic findings suggestive of MRONJ), but these patients do not fit the criteria for the diagnosis of MRONJ. In the orthopedic literature, the usefulness of a Stage 0 category has been established for staging avascular necrosis (AVN) of the femoral head when there is a suspicion of AVN in a patient at risk, but the diagnostic information is not conclusive.[39] AAOMS believes the Stage 0 category for MRONJ is analogous in principle and does account for the wide-ranging radiographic presentation of MRONJ that exists prior to overt bone exposure. Therefore, AAOMS has decided to maintain the current classification system with no modifications.

PATIENTS AT-RISK

No apparent necrotic bone in asymptomatic patients who have been treated with IV or oral antiresorptive therapy.

STAGE 0 (NONEXPOSED BONE VARIANT)

Patients with no clinical evidence of necrotic bone but who present with nonspecific symptoms or clinical *and* radiographic findings, such as:

Symptoms

- Odontalgia not explained by an odontogenic cause.
- Dull, aching bone pain in the jaw, which may radiate to the temporomandibular joint region.
- Sinus pain, which may be associated with inflammation and thickening of the maxillary sinus wall.
- Altered neurosensory function.

Clinical Findings

- Loosening of teeth not explained by chronic periodontal disease.
- Intraoral or extraoral swelling.

Radiographic Findings

- Alveolar bone loss or resorption not attributable to chronic periodontal disease.
- Changes to trabecular pattern sclerotic bone and no new bone in extraction sockets.
- Regions of osteosclerosis involving the alveolar bone and/or the surrounding basilar bone.
- Thickening/obscuring of periodontal ligament (thickening of the lamina dura, sclerosis, and decreased size of the periodontal ligament space).[40]

These nonspecific findings, which characterize this variant of MRONJ without bone exposure, may occur in patients with a prior history of Stage 1, 2, or 3 disease who have been healed and have no clinical evidence of exposed bone. Progression to Stage 1 disease has been reported in up to 50 percent of

patients with Stage 0 disease[41] and, therefore, AAOMS deems it prudent to consider Stage 0 disease as a potential precursor to MRONJ.

STAGE 1

Exposed and necrotic bone or fistula that probes to the bone in patients who are asymptomatic and have no evidence of infection/inflammation. These patients also may present with radiographic findings mentioned for Stage 0 that are localized to the alveolar bone region.

STAGE 2

Exposed and necrotic bone, or fistula that probes to the bone, with evidence of infection/inflammation. These patients are symptomatic. These patients also may present with radiographic findings mentioned for Stage 0 localized to the alveolar bone region.

STAGE 3

Exposed and necrotic bone or fistulae that probes to the bone, with evidence of infection, and one or more of the following:

- Exposed necrotic bone extending beyond the region of alveolar bone (ie, inferior border and ramus in the mandible, maxillary sinus, and zygoma in the maxilla)
- Pathologic fracture.
- Extraoral fistula.
- Oral antral/oral-nasal communication.
- Osteolysis extending to the inferior border of the mandible or sinus floor.

CAUSALITY

It is important to understand that patients at risk for or with established MRONJ also can present with other common clinical conditions not to be confused with MRONJ. Commonly misdiagnosed conditions may include but are not limited to alveolar osteitis, sinusitis, gingivitis/periodontitis, caries, periapical pathology, odontalgia, atypical neuralgias, fibro-osseous lesions, sarcoma, chronic sclerosing osteomyelitis, and temporomandibular joint (TMJ) disorders. It also is important to remember that delayed healing, exposed bone or sequestra (ie, osteonecrosis [ONJ]), can occur in patients not exposed to antiresorptive agents.[42]

Proving causality of any medication-related complication is challenging from an epidemiologic perspective. It is well-known that MRONJ is a rare entity, multifactorial in nature, and patients with the same clinical presentation exist who have not been exposed to an antiresorptive medication. Studies have reported jaw necrosis in antiresorptive naïve patients in which necrosis was linked to bacterial, viral, or fungal infections, trauma, smoking, steroids, immunocompromised host, autoimmune diseases, diabetes, and chemotherapy.[43-57] Furthermore, patient populations, such as those with osteogenesis imperfecta have been treated with antiresorptive agents without reports of MRONJ.[58] Many patients receiving medications associated with MRONJ have other comorbidities, which are likely exacerbating or contributing factors. In combination, these confounding variables make incidence and prevalence difficult to estimate.

Clinical trials, while being the gold standard for efficacy and safety data, are seldom powered to demonstrate uncommon events. Prior to the discovery of MRONJ, large randomized prospective trials of BPs with up to 10 years of patient data did not reveal any jaw bone necrosis as a complication.[17,59] More recently, the HORIZON Pivotal Fracture trial tested 3,889 randomized patients given annual zoledronic acid versus placebo for 3 years; one patient developed MRONJ in the intervention group and one in the placebo group.[18] Extension of this trial for up to 6 years resulted in one additional MRONJ patient in the treatment group.[60] Extension to 9 years resulted in no additional confirmed cases of MRONJ.[61]

Definitive causality, taken as a whole, remains a difficult task to prove in general, let alone in individual patients presenting with clinical symptoms. Clinicians should be aware of these facts in decisions regarding treatment recommendations.

PATHOPHYSIOLOGY

Since the AAOMS position paper in 2014, significant knowledge has been gained regarding MRONJ pathophysiology from both clinical and particularly preclinical animal studies. It should be noted that animal studies have a number of limitations, are most often using supratherapeutic doses and likely do not truly mirror the clinical environment. That said, they are critical in understanding disease mechanisms and can serve as one reference point to evidence-based clinical decision-making.

Much debate persists among clinicians and researchers, contributing to the various treatment protocols utilized for patients today.[62-65] Disease specificity unique to the jaws has focused leading hypotheses to include bone remodeling inhibition, inflammation or infection, angiogenesis inhibition, innate or acquired immune dysfunction, as well as genetic predisposition.[3,65] Both animal and human studies suggest that an antiresorptive medication, coupled with inflammation or infection, is necessary and

sufficient to induce MRONJ. However, as more knowledge is gained on the subject, it is becoming increasingly apparent that MRONJ is multifactorial, and it is likely that multiple hypotheses can explain the overall pathophysiology of this disease.[3,65]

Bone Remodeling Inhibition

The definition of MRONJ includes oral or parenteral administration of antiresorptive medications, such that bone remodeling suppression is a central hypothesis in its pathophysiology. Antiresorptive medications, including BPs and denosumab (DMB), have direct effects on osteoclast formation, differentiation, or function. In osteoporosis, BPs are a first-line therapy to decrease bone remodeling, increase bone mineral density, and decrease vertebral and long bone fractures.[66,67] BPs, in higher doses, also are utilized in primary bone malignancy and bone metastases to decrease SREs, including hypercalcemia of malignancy, reduce severe bone pain, and improve quality of life.[68-72] Although DMB has only been approved for use since 2010, its use has increased significantly for both osteoporosis and malignancy in the last decade. Prevalence of MRONJ with DMB users is at least as high as BP users, likely due to its increased potency to inhibit bone resorption.[30,73-75] This is supported in the jaws as animal studies demonstrate absent osteoclasts around the alveolar bone of DMB-treated mice.[76] Human bone specimens also show an increased number of nonfunctional osteoclasts surrounding necrotic bone in BP-treated patients,[77] further reinforcing bone remodeling inhibition as a leading hypothesis in MRONJ pathophysiology. With the appearance of MRONJ in DMB-treated patients, it becomes increasingly apparent that the underlying pathophysiology involves dysfunctional osteoclasts.

Animal studies evaluating withdrawal of BPs or DMB further highlight the importance of bone remodeling in MRONJ prevention and resolution. Rodents with established ONJ failed to resolve when antiresorptive were withdrawn. However, discontinuing DMB, but not BPs, prior to tooth extraction successfully prevented MRONJ development in rats.[78,79] Moreover, parathyroid hormone, which acts directly on osteoblasts to induce bone formation and indirectly increases osteoclastic bone resorption and overall remodeling, has been shown to prevent MRONJ and improve extraction socket healing in rodents and preliminarily in patients.[80-82] This observation provides further support for the central role of osteoclast inhibition in MRONJ pathogenesis.

Inflammation or Infection

Although most studies report tooth extraction as the major inciting event for MRONJ development, it is clear that most extracted teeth had pre-existing periodontal or periapical disease.[3,64,83,84] From this patient information, animal models of inflammation or infection were developed to replicate clinical, radiographic, and histologic features of MRONJ.[85-88] Presence of inflammatory cytokines, specifically at the site of MRONJ, also support the strong role of inflammation.[89] As evidence of increased systemic inflammation and its contribution to MRONJ development, mice with experimentally induced rheumatoid arthritis demonstrated more severe MRONJ with increased oral bone exposure, more pronounced radiographic features, intense local inflammatory infiltrate, and larger areas of histologic necrosis.[90] Further support for the inflammatory etiology showed that removal of the inflammatory nidus in ligature-induced pericdontitis ameliorated MRONJ development in mice, demonstrating reduced inflammation and prevention of disease progression.[91] Moreover, transplantation of peripheral blood mononuclear cells with anti-inflammatory properties reduced MRONJ prevalence by improving soft-tissue healing, decreasing inflammatory polymorphonuclear cells and inflammatory marker expression, as well as enhancing vascularity.[92] These preclinical findings confirm the irrefutable role of inflammation or infection in MRONJ disease prevalence, severity and resolution.

The presence of bacteria on the exposed necrotic bone also contributes to disease severity, where pain and signs of infection define Stage 2 MRONJ.[3,93,94] This is not surprising since poor oral hygiene and biofilm presence are associated with MRONJ development,[95,96] and oral health maintenance and dental prophylaxis before initiating antiresorptive therapy can decrease MRONJ prevalence.[97,98] Importantly, clinical treatment protocols to reduce the biofilm and eradicate infection have emerged as important alternatives to debridement and resection in patients who may not be ideal surgical candidates.[63]

Angiogenesis Inhibition

Osteonecrosis is traditionally defined as avascular necrosis or aseptic necrosis, most commonly characterized as osteocyte death after decreased blood flow to the femoral head.[99] However, MRONJ is defined as necrotic bone in the maxillofacial region after exposure to either antiresorptive or antiangiogenic medications.[3] BPs such as zoledronic acid directly inhibit angiogenesis in vitro and in vivo[100-103] and animal models demonstrate decreased vascularity in sites of MRONJ and decreased microvessel numbers during early stages of bone healing.[104] In addition, angiogenesis normally seen during extraction socket healing is inhibited by BPs, and both BPs and DMB have been shown to decrease arterial area, venous area, and overall vascularity of periodontal tissues during

early and late MRONJ development.[105,106] Importantly, antiangiogenic medications, such as VEGF inhibitors, tyrosine kinase receptor inhibitors, and immunomodulatory drugs,[107-109] can be associated with MRONJ. Moreover, patients with multiple myeloma receiving both antiresorptive and antiangiogenic medications, as shown in several studies,[110-114] have a higher MRONJ prevalence. Important aspects of MRONJ treatment include determining disease margins, which can be challenging as microvascular mucosal abnormalities can be seen adjacent to frank MRONJ lesions.[115] It is important to note that the incidence of MRONJ in patients on antiangiogenics is much lower than those taking antiresorptive medications.

Innate or Acquired Immune Dysfunction

Although animal studies confirm that an antiresorptive medication—coupled with inflammation or infection—is necessary and sufficient to produce MRONJ, not all patients with dental infections develop the disease. It is well-known that patients with medical comorbidities such as diabetes or rheumatoid arthritis or immunocompromised states are at significantly higher risk for MRONJ with or without exposure to antiresorptive agents.[3,64,114,116] Patients with metastatic or primary bone malignancies have a compromised immune system.[117] This also has been confirmed with animal studies, where chemotherapy, steroids, and disease-modifying antirheumatic drugs (DMARDs), combined with antiangiogenic medications and an antiresorptive, increase MRONJ severity or prevalence.[118-120] Moreover, higher rates of MRONJ occur in patients with multiple myeloma who receive multiple chemotherapeutic agents.[110,121]

Replenishing the area of nonhealing MRONJ lesions with mesenchymal stem cells (MSCs) to overcome immune dysfunction is a potential area of therapeutic interest, especially in patients who are immunocompromised. A recent study showed altered numbers and patterns of T-cells in human and rat MRONJ necrotic bone samples as compared to healthy patients and non-MRONJ sites.[122] Preclinical studies also demonstrate healing or prevention of MRONJ lesions after systemic infusion with adipose or bone marrow-derived MSCs.[123-125]

Genetic Factors

In the 2014 paper, the authors identified several reports describing single-nucleotide polymorphisms (SNPs) that were associated with the development of MRONJ. Most of these SNPs were located within regions of the gene associated with either bone turnover, collagen formation, or certain metabolic bone diseases. Indeed, increasing evidence is available to support the role of SNPs with MRONJ.[126,127] Specific links to sirtuin-1 (SIRT1), a bone remodeling regulator that promotes bone formation, may be protective against MRONJ if upregulated.[128] SIRT1 also is involved in both reduction of inflammation and induction of angiogenesis, suggesting a role in several of the leading MRONJ hypotheses.[128] Other genes also have been reported to increase MRONJ risk through their role in angiogenesis, bone remodeling, and immune responses, including PPAR gamma, CYP2C8, and many others.[129] Collectively, these studies suggest that MRONJ is a multifactorial disease and that genetic factors may play a role in its development.[130] Overall, however, current studies document either a weak or no association between genetic factors measured and risk for MRONJ.[131] To determine predisposition, studies with larger sample sizes should be performed, with genetic risks confirmed in both BPs and DMB-treated patients who have breast or prostate cancer metastases, multiple myeloma, or osteoporosis.

Risk Factors for MRONJ

MEDICATION-RELATED RISK FACTORS

To estimate the risk for medications associated with MRONJ, the primary parameter to be considered is the therapeutic indication for treatment (eg, malignancy or osteoporosis/osteopenia). The data suggest that antiresorptive medications (ie, BPs and DMB) are associated with an increased risk for developing MRONJ. The risk of MRONJ is considerably higher in the malignancy group (<5%) than in the osteoporosis group (<0.05%). Current data are insufficient to identify other medications as risk factors for developing MRONJ.

MRONJ risk among cancer patients

For estimating the risk for MRONJ among patients exposed to a medication, the risk for MRONJ in patients *not exposed* to antiresorptive medications must be estimated (Table 1). The risk for MRONJ among cancer patients enrolled in clinical trials and assigned to *placebo* groups ranges from 0 percent to 0.7 percent.[132-138]

a. Among cancer patients exposed to zoledronate, the cumulative risk of MRONJ clusters in the low single digits, <5 percent, and ranges from 0 percent to 18 percent.[113,132,133,137-144] The wide variation in estimates may be explained by the varying durations of follow-up, one to 10 years, reported in the various studies. The risk of MRONJ among cancer patients exposed to zoledronate ranges between 2-10 times higher than cancer patients treated with placebo.
b. Among cancer patients exposed to DMB, the risk of MRONJ ranges from 0 percent to 6.9 percent, with most studies reporting rates <5

Table 1. MRONJ DISEASE FREQUENCY GROUPED BY INDICATIONS FOR TREATMENT VERSUS MEDICATION*

Indications for Treatment	Medication					Study Design
	Placebo	Zoledronate	Oral BPs	Denosumab	Romosozumab	
Malignancy						
Coleman (2020)[138]	0.2% (2,218)*			5% (2,241)		RCT†
O'Carrigan et al, (2017)[137]	0.7% (6,788)			0.4% (6,788)		Systematic review
O'Carrigan et al, (2017)[137]	0% (3,060)	1% (3,078)				Systematic review
Macherey et al, (2017)[136]	0.7% (818)	1.5% (808)				Systematic review
Gnant et al, (2015)[247]	0% (903)	0% (900)				RCT
Coleman et al, (2014)[133]	0% (1,679)	1.7% (1,681)				RCT
Valachis et al, (2013)[132]	0% (3,039)	0.52% (4,774)				Systemic review
Boquete-Castro et al, (2016)[135]	0.1%	1.14%		1.7%		Systematic review
Coleman (2020)[138]	0.2% (2,218)			5.4% (2,214)		RCT
Gnant et al, (2015)[247]	0% (1,709)			0% (1,711)		RCT
Raje et al, (2018)[113]		2.8% (82)		4.1% (850)		RCT
Himelstein (2017)[140]		1.5% (1,822)				RCT
Henry (2014)[141]		1.1% (786)		0.8% (792)		RCT
Yang et al, (2019)[248]		2% (8,525)				Systematic review
Peddi et al, (2013)[142]		1.3% (2,846)		1.8% (2,885)		Systematic review
Ng et al, (2021)[145]		1.6-4%‡ 3.8-18%§		1.9%‡ 6.9%§		Systematic review
Wang et al, (2014)[144]		1.4% (1,013)		2% (1,020)		Systematic review
Osteoporosis						
Papapoulos et al, (2012)[26]	0% (3,383)			0.04% (4,549)		RCT
Grbic et al, (2010)[150]	0.02% (4,945)	0.02% (5,864)				Systematic review
Cosman et al, (2016)[151]	0% (3,322)				0.03% (3,321)	RCT
Saag et al, (2017)[37]			0.05% (2,047)		0.05% (2,046)	RCT
Bone et al, (2017)[153]				0.3% (2,343) 10-yr f/u		RCT
Hallmer et al, (2018)[75]			0.043%			Population study (50,000)
Nonmalignant bone disease						
Chawla et al, (2019)[156]				5% (532)		Prospective case series
Rutkowski[155]				0.7% (138)		Retrospective case series

* Sample size in parentheses
† Randomized clinical trial.
‡ <2 years of follow-up.
§ >2 years of follow-up.

Ruggiero et al. AAOMS' Position Paper on MRONJ—2022 Update. J Oral Maxillofac Surg 2022.

percent.[113,134,135,138,141,142,144,145] The risk for MRONJ among cancer patients exposed to DMB is comparable to the risk of MRONJ in cancer patients exposed to zoledronate.[135,141,142,144,145]

Since the 2014 update, investigators have implicated numerous families of medications as risk factors for MRONJ.[146-149] These medications include tyrosine kinase inhibitors (TKIs) such as sunitinib, monoclonal antibodies (bevacizumab), fusion proteins (aflibercept), mTOR inhibitors (everolimus), radiopharmaceuticals (radium 223), selective estrogen receptor modulators (raloxifene), and immunosuppressants (methotrexate and corticosteroids).

When compared to antiresorptive medications, the level of evidence supporting other medication families as risk factors for MRONJ is level 5 (eg, isolated case reports or mini-case series [<5 cases]).[146-149] Given that the poly-pharmaceutical management of cancer patients combined with the fact that cancer and immunosuppression are risk factors for MRONJ without exposure to antiresorptive agents, AAOMS believes that identifying a single medication as being the etiologic agent for MRONJ seems unlikely in case reports or mini-case series. Further controlled prospective studies will be required to measure the risk of MRONJ associated with non-antiresorptive agents.

MRONJ Risk Among Osteoporosis Patients

Most dentists and oral and maxillofacial surgeons evaluate patients in their practices exposed to antiresorptive therapy for management of osteoporosis (Table 1).

a. Risk for MRONJ among osteoporotic patients exposed to BPs.

The risk of MRONJ among study subjects assigned to placebo groups enrolled in osteoporosis clinical trials ranged from 0 percent to 0.02 percent.[26,150,151] Among study subjects treated with BPs, the risk of MRONJ is 0.02 percent to 0.05 percent.[37,75,152] Among patients exposed to IV zoledronate, the risk for MRONJ is estimated to be ≤0.02% (≤ 2 per 10,000). For patients exposed to oral bisphosphonates, MRONJ risk is estimated to be ≤0.05% (≤ 5 per 10,000).

b. MRONJ risk among osteoporotic patients exposed to RANK-L inhibitors.

After 10 years of follow-up, among patients exposed to DMB, the risk for MRONJ was reported to be 0.3 percent, almost an order of magnitude higher than for BPs.[153]

c. The risk for MRONJ when exposed to romosozumab (0.03 percent to 0.05 percent) is comparable to alendronate (0.05 percent).[37,151] In the placebo group, there were no cases of MRONJ.[151] It will be important to continue to monitor romosozumab to assess its role as a risk factor for MRONJ.

The risk for MRONJ among osteoporosis patients treated with BPs ranges from 0.02 percent to 0.05 percent and overlaps the risk for MRONJ of patients enrolled in placebo groups (0 percent to 0.02 percent). The risk for MRONJ among patients treated with denosumab, however, has a larger range—from 0.04 percent to 0.3 percent. As such, additional research will be needed to better estimate the risk of MRONJ among patients receiving denosumab. The risk of MRONJ for patients exposed to romosozumab (0.03 percent to 0.05 percent) more closely aligns with the risk associated with BPs.[37,151] However, given its recent introduction as a therapeutic agent, additional research will be needed to refine its association and risk estimate for MRONJ.

Based on this current review of data, the risk of developing MRONJ among osteoporotic patients exposed to BPs, DMB, and romosozumab is low. The occurrence of cases seen is best explained by a rare event among a large number of patients, 5.1 million over the age of 55, exposed to these drugs.[154]

MRONJ Risk Among Patients with Nonmalignant Bone Disease

a. AAOMS identified two studies where DMB was used to manage aggressive giant cell tumors of bone.[155,156] The risk of developing MRONJ in the two studies was broad and ranged from 0.7 percent to 5 percent. This is comparable to the risks of developing MRONJ in subjects treated with DMB for malignancies (range = 0 percent to 6.9 percent). Additional studies will be needed to confirm the risk estimate for MRONJ among patients with nonmalignant bone disease treated with antiresorptives.
b. There are very limited data describing the occurrence of MRONJ in the pediatric population for osteogenesis imperfecta and other conditions. In a systematic review estimating the risk of MRONJ among children with osteogenesis imperfecta, there were no cases of MRONJ identified in a sample of 486 subjects treated for 4.5 to 6.8 years.[157] In a different systematic review that estimated the risk for MRONJ among those under the age of 24 for several conditions treated using BPs, no cases of MRONJ were reported.[158]

The overall quality of the studies included in both systematic reviews was limited by small sample sizes or lack of MRONJ-related risk factors.

Duration of Medication Therapy as a Risk Factor for MRONJ

Regardless of indications for therapy, the *duration of antiresorptive therapy* is a risk factor for developing MRONJ. Among cancer patients exposed to zoledronate or DMB (n = 5,723), the risk of developing MRONJ was, respectively, 0.5 percent and 0.8 percent at 1 year, 1.0 percent and 1.8 percent at 2 years, and 1.3 percent and 1.8 percent at 3 years.[141] In a study by Saad et al, the investigators combined three-blinded phase three trials and found similar results, including a plateau after 2 years for patients exposed to DMB.[5] In a more recent systematic review by Ng et al, the risk of MRONJ among cancer patients treated with zoledronate, was 1.6 percent to 4 percent after 2 years of treatment and 3.8 percent to 18 percent with more than 2 years of treatment.[145] Likewise, for DMB, the risks for developing MRONJ were 1.9 percent and 6.9 percent with <24 months and >24 months of exposure, respectively.[145]

For patients receiving bisphosphonate therapy to manage osteoporosis, data regarding duration are mixed. Early on, the prevalence of MRONJ was reported as increasing over time from near 0 percent at baseline to 0.21 percent after four or more years of BP exposure based on retrospective analysis.[152,159] More recent data from a large prospective, randomized placebo controlled trial demonstrate no significant increase in MRONJ in patients treated for up to 9 years.[18,60,61] In addition, there are no postmarketing data or general clinical experience to support an MRONJ prevalence of 0.21 percent in any osteoporosis-treated group. Therefore, while duration may be a risk factor, the overall risk remains low.

LOCAL FACTORS

Dentoalveolar Operations

Dentoalveolar operations are the most common identifiable predisposing factor for developing MRONJ. Several studies report that among patients with MRONJ, tooth extraction is cited as a predisposing event ranging from 62 percent to 82 percent.[5,75,160] While this information is important, it is not what most patients or clinicians want to know. Most providers and patients want an answer to the following clinical question: "Among patients exposed to antiresorptive medications, what is the risk for developing MRONJ following tooth extraction (or other dentoalveolar procedures such as implant placement or periodontal procedures)?" Current estimates for the risk of MRONJ among osteoporotic patients exposed to BPs following tooth extraction range from 0 percent to 0.15 percent.[161,162] For osteoporotic patients exposed to DMB, the risk for MRONJ following tooth extraction was 1 percent.[163]

For cancer patients exposed to BPs, the risk of developing MRONJ after tooth extraction ranges from 1.6 percent to 14.8 percent.[164-166] In a small case series, n = 61 subjects having 102 extractions, the risk for MRONJ after tooth extraction was 13.1 percent.[167] In a systematic review by Gaudin et al, the risk for MRONJ after tooth extraction (n = 564) was estimated to be 3.2 percent.[162] While the estimates for developing MRONJ in high-risk patients undergoing tooth extraction vary, they cluster between 1 percent and 5 percent, similar to estimates of osteoradionecrosis following tooth extraction in irradiated patients.

The risk of developing MRONJ among patients who have been exposed to antiresorptive medications for other dentoalveolar operations such as dental implant placement and endodontic or periodontal procedures is unknown.[168] The risk for MRONJ after implant placement among patients treated with DMB has been reported to be 0.5 percent.[163] Absent better data, AAOMS cautions the use of these procedures in cancer patients exposed to antiresorptive therapies and recommends osteoporosis patients be informed of potential risks, albeit low, including development of MRONJ, early and late implant failure all of which have been described in case reports and clinical trials.

Anatomic Factors

Limited new information regarding anatomic risk factors for MRONJ is available. MRONJ is more likely to appear in the mandible (75 percent) than the maxilla (25 percent) but can appear in both jaws (4.5 percent).[5,75] Denture use was associated with an increased risk for MRONJ among cancer patients exposed to zoledronate (OR = 4.9; 95 percent CI = 1.2 to 20.1).[169] In a study by Vahtsevanos et al, a sample of 1,621 cancer patients treated with intravenous zoledronate, ibandronate or pamidronate, there was a two-fold increased risk for MRONJ among denture wearers.[170]

Concomitant Oral Disease

Pre-existing inflammatory dental disease such as periodontal disease or periapical pathology is cited as a risk factor.[75,168] Among cancer patients with MRONJ, the pre-existing inflammatory dental disease was a risk factor among 50 percent of the cases.[5,165]

Given that a common treatment of inflammatory dental disease is tooth extraction, pre-existing dental disease may confound the relationship between tooth

extraction and risk for MRONJ. Tooth extraction may expose MRONJ as opposed to being the precipitating event. It would be valuable to see an estimate of the association between tooth extraction and MRONJ adjusted for pre-existing inflammatory dental disease.

After tooth extraction and periodontal disease, the next most common risk factor is reported as "spontaneous" MRONJ with no identifiable dental risk factor.[168]

DEMOGRAPHIC AND SYSTEMIC FACTORS AND OTHER MEDICATIONS

Age and sex are variably reported as risk factors for MRONJ.[5,165,169-171] The higher prevalence of MRONJ in the female population is likely a reflection of the underlying disease for which the agents are being prescribed (eg, osteoporosis, breast cancer).

As noted previously, those under the age of 24 treated with antiresorptives for benign bone diseases have not demonstrated any risk for MRONJ even after an extended duration of therapy. The overall quality of the studies included even in systematic reviews is based on small sample sizes and the lack of other MRONJ-related risk factors. The risk of developing MRONJ in the pediatric population requires continued surveillance.

Corticosteroids are associated with an increased risk for MRONJ.[5,168,171] There are concerns that corticosteroids increase the risk for MRONJ when given in conjunction with antiresporptive agents.

Comorbid conditions are inconsistently reported to be associated with an increased risk for MRONJ, including anemia (hemoglobin < 10 g/dL) and diabetes.[5,171] Cancer type also is variably reported as a risk factor.[170,172]

Tobacco use is variably reported as a risk factor for MRONJ. In a case-control study, tobacco use approached statistical significance as a risk factor for MRONJ in cancer patients (OR = 3.0; 95 percent CI = 0.8 to 10.4).[169] In a more recent case-controlled study, tobacco use was not associated with ONJ in a sample of cancer patients exposed to zolendronate.[171] Vahtsevanos did not report an association between tobacco use and MRONJ.[170]

In brief, after chemotherapy and corticosteroid exposure, the next most reported comorbidity is "no comorbidity."[168]

In summary, the current literature reaffirms that the risk of MRONJ is significantly greater in cancer patients receiving antiresorptive therapy compared to patients receiving antiresorptive therapy for osteoporosis. Moreover, the risk of MRONJ in osteoporosis patients receiving antiresorptive therapy continues to be very low regardless of drug type (BPs, DMB, romoszumab) or dosing schedule.

Management Strategies

TREATMENT GOALS

The major goals of treatment for patients at risk of developing or who have established MRONJ are:

- Prevention of MRONJ (see section MRONJ risk among cancer patients below).
- Prioritization and support of continued oncologic treatment in patients receiving antiresorptive therapy alone or in combination with immune modulators or antiangiogenic medications:
  - Oncology patients benefit from the therapeutic effect of antiresorptive therapy by controlling bone pain and reducing the incidence of other SREs.
- Prioritization and support of continued bone health and the prevention of fragility fractures
  - Patients with osteoporosis, osteopenia, and other metabolic bone diseases benefit from antiresorptive therapy by significantly reducing the risk of fragility fractures and other skeletal-related events.
- Preservation of quality of life through:
  - Patient education and reassurance.
  - Control of pain.
  - Control of secondary infection.
  - Prevention of extension of lesion and development of new areas of necrosis.

PREVENTION OF MRONJ

Numerous studies demonstrate potentially modifiable factors for reducing the risk of MRONJ, including performing high-risk surgical procedures prior to initiating therapy,[95,173-175] using preoperative and postoperative antibiotics and antimicrobial mouth rinses,[174,176-180] primarily closing extractions sites,[176-178] and maintaining good oral hygiene.[95,166,176,177,181] Maximizing overall patient health is always indicated, such as smoking cessation and diabetes optimization. Although no individual strategy nor collection of strategies eliminates all MRONJ risks, these preventive procedures are recommended.

The prevention of MRONJ begins with the realization that patients receiving antiresorptive therapies may have altered osseous wound-healing capacity, which may also be a risk for developing MRONJ. Similar to other common preventive strategies in medicine and dentistry, healthcare providers need to recognize the importance of coordinated dental care and pretreatment management in minimizing the risk of MRONJ. This requires a continuous effort to educate patients, dentists, and medical professionals

about the real risks associated with these therapies and clinical prevention paradigms that can mitigate MRONJ development.

AAOMS re-emphasizes the importance of a multidisciplinary approach to the treatment of patients who are receiving antiresorptive therapies. This may also apply to other immune modulators or targeted therapies taken alone or in combination with antiresorptives. This approach includes consultation with an appropriate dental professional when it is determined a patient would benefit from these therapies.

Optimization of Oral Health

The 2014 AAOMS position paper identified valid prophylactic treatment strategies that reduce the incidence of MRONJ. The efficacies of these strategies remain validated by subsequent studies that demonstrate the importance of pretreatment dental screening and regimented dental surveillance. There is a robust level of support for early screening and initiation of appropriate dental care prior to the initiation of antiresorptive therapy.[38,182-186]

These preventive management strategies not only decrease the risk for MRONJ but accrue the benefits that all patients enjoy with optimum oral health.[186-193]

In a prospective study of prostate cancer patients with bone metastasis, instituting a more regimented dental health surveillance system resulted in a 2.5-fold reduction in relative risk compared to symptomatically driven dental treatment.[186] In a systematic review aimed at identifying prevention strategies associated with tooth extractions in patients at risk for MRONJ, no randomized clinical trials were reported.[194] However, there are many animal studies that demonstrate that periodontal or periapical inflammation plays a key role in creating a local environment that supports the development of bone necrosis in the context of systemic antiresorptive therapy.[85,91,195,196]

Treatment planning for patients at risk of developing MRONJ should include a thorough examination of the oral cavity and a radiographic assessment when indicated. It is important to identify both acute infection and sites of potential infection to prevent future sequelae that could be exacerbated once drug therapies begin. Considerations during the clinical and radiographic assessment include patient motivation, patient education regarding dental care, fluoride application, chlorhexidine rinses, tooth mobility, periodontal disease, presence of root fragments, caries, periapical pathology, edentulism, and denture stability.[197]

An additional benefit of early dental consultation, when the use of antiresorptive therapy is being considered, is that the patient is informed of the risk associated with these drug therapies and the risk incurred by not undergoing recommended dental preventive measures before consenting to treatment.

Cessation of At-Risk Medication Therapy (Drug Holiday) Prior to Tooth Extraction or Other Procedures that Involve Osseous Injury (eg, Dental Implant Placement, Periodontal or Apical Endodontic Treatment)

The clinical practice of antiresorptive drug holidays to mitigate MRONJ risk in patients undergoing dentoalveolar surgery was controversial at the time of the previous AAOMS position paper in 2014 and remained the case in 2021. While the practice of a drug holiday has been accepted and recommended by several international professional societies,[3,38,182,183,198] the evidence to support or refute such positions remains inconclusive. The difficulty in establishing or refuting the efficacy of drug holidays is due to the rarity of MRONJ in these patient populations. Therefore, since few events are reported, randomized-controlled trials provide insufficient data to create sound treatment protocols. In a 2020 systematic review that studied the efficacy of antiresorptive drug holiday in preventing MRONJ, a variety of papers were identified with differing conclusions suggesting that a high level of evidence for supporting or refuting the use of a holiday is missing.[199]

The historical use of a drug holiday was intended to decrease the prevalence of MRONJ subsequent to the performance of high-risk surgical procedures. The concern regarding this practice is the loss of efficacy of antiresorptive therapy with the development of SREs and fragility fractures. Among others, factors for consideration may include disease-related risk (cancer vs osteoporosis), drug-dosing frequency, duration of therapy, comorbidities, other medications (especially chemotherapy, steroids, or antiangiogenics), degree of underlying infection/inflammation, and extent of surgery to be performed.

Of note, the working group was unable to reach a consensus regarding a recommendation on drug holidays and was evenly split between offering drug holidays to patients on a case-by-case basis using prior recommendations and those who never recommend drug holidays, believing that the risks of potential deleterious effects of suspending antiresorptive therapy may outweigh a benefit.

A special concern should be considered for suspending RANKL inhibitors in osteoporosis patients. Several studies have demonstrated a rebound increase in bone resorption following the discontinuation of DMB, resulting in an increased risk of multilevel vertebral fractures.[200-202] If DMB is to be suspended, the timing and duration of the holiday should be optimized in order to minimize this risk. The planned dentoalveolar surgery can be completed 3-4 months following the last dose of

Table 2. MRONJ PREVENTION STRATEGIES

Pretherapy (Nonmalignant Disease)	• Educate patient about the potential risks associated with long-term ART.* • Optimization of dental health can occur concurrent with ART.
Pretherapy (malignant disease)	• Educate patients about the higher risk of MRONJ and the importance of regimented dental care. • Optimization of the dental health *prior* to the initiation of ART if systemic conditions permit (extraction of nonrestorable teeth or teeth with a poor prognosis).
During antiresorptive therapy (nonmalignant disease)	• No alteration of operative plan for most patients. • Considerations include drug schedule, duration of therapy, comorbidities, other medications (especially chemotherapy, steroids, or antiangiogenics), degree of underlying infection/inflammation, and extent of surgery to be performed. Drug holidays are controversial. • BTM† are not a useful tool to assess MRONJ risk.
During antiresorptive therapy/ targeted therapies (malignant disease)	• Educate patients about the higher MRONJ risk in the setting of malignant disease. • Educate the patient about the importance of regimented dental care and prevention. • Avoid dentoalveolar surgery if possible. • Consider root retention techniques to avoid extractions. • Dental implants are contraindicated. • Drug holidays are controversial.

* Antiresorptive therapies.
† Bone turnover markers (CTX).

Ruggiero et al. AAOMS' Position Paper on MRONJ—2022 Update. J Oral Maxillofac Surg 2022.

DMB when the level of osteoclast inhibition is waning. It can then be reinstituted 6-8 weeks postsurgery. This management strategy minimizes the length of the drug holiday while maintaining a favorable environment for bone healing.

Bone Turnover Markers. Since the 2014 AAOMS position paper, there has been a shift away from bone turnover markers. No biomarkers are validated for clinical decision-making, and continued research and prospective studies are required before these markers can be considered efficacious tools in estimating MRONJ risk.

Other Biomarkers

Biomarkers related to angiogenesis, VEGF activity, endocrine function, and PTH have more recently been described.[203-205] These markers remain at an exploratory stage and are not yet validated for clinical decision-making.

PREVENTION STRATEGIES

Patients scheduled to initiate antiresorptive treatment for cancer therapy

The treatment objective for this group of patients is to minimize the risk of developing MRONJ (Table 2). Although a small percentage of patients receiving antiresorptives develop osteonecrosis of the jaw spontaneously, the majority of affected patients experience this complication following dentoalveolar surgery.[5,112,165,206,207] Therefore, *if systemic conditions permit*, initiation of antiresorptive therapy should be delayed until dental health is optimized.[173,208] This decision must be made in conjunction with the treating physician and dentist and other specialists involved in the care of the patient. There is widespread consensus that optimizing dental health prior to initiating therapy is efficacious and of paramount importance.[38,185,186,209] Medical oncologists should educate their patients about the importance of dental health and the efficacy of prophylactic dental treatment in the prevention of MRONJ. Similar to patients who are to receive radiation therapy, optimizing the dental health in patients receiving antiresorptives or other therapies that can compromise bone healing is essential. The pretreatment evaluation of dental health must extend beyond a review of systems and include a physical and radiographic exam. Therefore, a comprehensive dental examination performed by a dental health professional would be a prudent approach for all patients prior to receiving antiresorptive therapy for malignant disease. This level of dental health assessment is most appropriately performed by a dental health professional.

The importance of minimizing the burden of dental infection and inflammation prior to dentoalveolar surgery in this cohort of patients with an elevated MRONJ risk cannot be over-emphasized. Nonrestorable teeth

and those with a poor prognosis should be extracted. Other necessary elective dentoalveolar surgery also should be completed at this time. It remains advisable that antiresorptive therapy should be delayed, *if systemic conditions permit,* until the surgical site(s) have mucosalized or until there is adequate osseous healing. Dental prophylaxis, caries control, conservative restorative dentistry, and nonoperative endodontic therapy are critical to maintaining functionally sound teeth. This level of care must be continued on a frequent and indefinite basis.[185]

The posterior lingual plate region is a common site for trauma and mucosal irritation in denture wearers.[5,75,170] Therefore, patients with full or partial dentures should be examined for areas of mucosal trauma, especially along the lingual flange region. It also is critical that patients be educated as to the importance of dental hygiene and regular dental evaluations, and specifically instructed to report any pain, swelling, or exposed bone.

Patients scheduled to initiate antiresorptive treatment for osteoporosis

Patients who are scheduled to receive antiresorptive therapy for the prevention of fragility fractures assume a significantly lower risk of MRONJ. Therefore, the urgency and the timing of optimizing the dental health are not as crucial. However, at the initiation of treatment, it would be prudent to educate patients regarding the potential risks of MRONJ. The importance of optimizing dental health throughout this treatment period and beyond cannot be underestimated.

It is not uncommon for patients to seek the consultation of an oral and maxillofacial surgeon in guiding their decision about starting or continuing antiresorptive therapy. In this scenario, the consulting oral and maxillofacial surgeon should use this opportunity to place the risks and benefits into the proper perspective. More specifically, patients should be reminded of the benefits associated with antiresorptive therapies in preventing fragility fractures and an acknowledgment of the rare occurrence of MRONJ.

The initial enthusiasm and attention associated with the discovery of MRONJ have had unintended consequences. When initially described, a "class effect" was observed, suggesting that MRONJ rates for patients receiving oncologic doses of BPs and those receiving osteoporotic doses of BPs were similar. A plateau and a decline in the use of BPs for osteoporosis was noted in 2006 and is hypothesized to be associated with various safety concerns, such as MRONJ. Patients are becoming increasingly more reluctant to begin or comply with their antiresorptive therapy. Current evidence also confirms an increase in fragility fractures with significant associated morbidity. As one salient example, hip fracture rates in the United States declined each year from 2002 to 2012 and then plateaued at levels higher than projected for 2013 to 2015, attributable to an "osteoporosis treatment gap."[210] Hip fracture carries significant morbidity, with only 40 percent to 60 percent of individuals recovering their prefracture level of mobility and ability to perform instrumental activities of daily living.[211] These data are representative of a true health crisis. The documented risk for developing MRONJ is low; however, the patient-perceived risk is not. As such, patients are unwilling to start or continue antiresorptive medical therapy. Patients are irrationally denying themselves the tangible therapeutic benefit of antiresorptive therapy to minimize the risk of fragility fractures in order to prevent a minuscule risk of developing MRONJ.

It is clear the benefit of fracture prevention outweighs the risk of MRONJ development in osteoporotic patients.[212] This benefit is even more favorable in the cancer population where bone-stabilizing medications significantly improve quality of life, and it is detrimental when antiresorptives are withheld due to MRONJ safety concerns.

Asymptomatic patients receiving antiresorptive therapies for cancer

Maintaining good oral hygiene and dental care is of paramount importance in preventing dental disease that may require eventual extractions or other dentoalveolar surgery. Procedures that involve direct osseous injury should be avoided if possible. If a dentoalveolar surgical procedure is unavoidable (eg, fractured tooth, advanced periodontal disease), patients should be informed of the associated risks. The benefit of a drug holiday remains unsubstantiated in this setting. Nonrestorable teeth may be treated by removal of the crowns and endodontic treatment of the remaining roots.[213] Teeth may be extracted if necessary. Placement of dental implants should be avoided in the oncology patient receiving parenteral antiresorptive therapy or antiangiogenic medications. Case series and systematic reviews have reported necrosis associated with antiresorptive therapy and implant placement.[194,214-216]

Asymptomatic patients receiving antiresorptive therapy for osteoporosis

Since the 2014 position paper, epidemiologic data regarding the risk of MRONJ in patients receiving antiresorptive therapy for osteoporosis remain limited due to the lack of sound prospective studies with sufficient power. Nevertheless, the risk for developing MRONJ is between 0.02 percent and 0.04 percent for BPs and 0.3 percent for DMB. (see

Table 1). Sound recommendations based on strong clinical research design are still lacking for patients taking oral BPs.

In general, elective dentoalveolar surgery does not appear to be contraindicated in this group. Risk assessment for the development of MRONJ in these patients includes the above-stated data and the discussion above related to drug holidays.

The placement of dental implants in the context of antiresorptive therapy for osteoporosis continues to be an area of research interest. Several systematic reviews have acknowledged the lack of quality data and randomized clinical trials. Some studies have recommended caution, especially with a longer duration of therapy or steroid use.[194,216] For example, in their systematic review, Granate et al,[216] identified several studies that reported an elevated MRONJ risk associated with implants placed in the posterior jaw if the duration of bisphosphonate therapy exceeded 3 years and if the patients were receiving systemic corticosteroids. In contrast to these studies, systematic reviews by Gelazius et al, and Stavropoulos et al, reported no increase in risk.[214,217] A recent retrospective propensity-matched cohort study of 44,900 patients reported a decreased risk of ONJ in osteoporosis patients receiving implants compared to matched controls who did not have implants. Of note, 9,738 patients had a history of BP use, and the results for implants was in contrast to risk increase for patients who underwent tooth extraction.[218]

Reports of implant-related (MRONJ) necrosis can be divided into the early (implant surgery-triggered) or late (implant presence-triggered) category.[215,219,220] In these reviews, the majority of the implant-related necrosis were not related to the initial implant surgery but occurred late (>12 months) and often at sites where implants were placed prior to the initiation of bisphosphonate therapy. The common presentation was an en bloc failure, where the osseointegration of the implants is maintained within the sequestrum.[220,221] This has been recognized as a separate pattern of failure that is distinct from the common peri-implantitis failure and considered by some to be pathognomonic of MRONJ. Although there are no prospective studies or systematic reviews pertaining to implant-related necrosis associated with RANKL inhibitors or other targeted therapies, AAOMS considers this to have a similar level of risk.

In summary, robust data do not exist, and available data are conflicting. Therefore, AAOMS suggests that if dental implants are placed, informed consent should be provided to include the low risk of MRONJ, as well as early and late implant failure. These patients should be placed on a regular long-term recall schedule.

Treatment Strategies

AAOMS has developed a series of treatment algorithms to streamline the evaluation (Fig 1) and management strategies (Figs 2-4) for patients with MRONJ. These strategies are based on a current review of nonoperative and operative therapies and their associated outcomes. Emphasis is placed on both nonoperative and operative management being acceptable for all stages of disease based on surgical judgment and patient factors in a shared decision-making model.

Nonoperative therapy

The efficacy of nonoperative therapies in the management of MRONJ is documented in the literature and provides a useful adjunct to the spectrum of management strategies that also include operative treatment (Fig 2). Nonoperative strategies can be useful in all stages, especially where significant comorbidities preclude operative treatment. They may also result in stabilization of disease or cure in earlier stages. The goal of both operative and nonoperative therapies remains the same: curative therapy and quality-of-life improvement. Nonoperative therapy heavily focuses on patient education, reassurance, control of pain, and control of secondary infection to allow for sequestration of the exposed, necrotic bone.[3,63]

Decisions on operative versus nonoperative therapy should be patient-specific and tailored to individual needs. The risk versus benefit ratio (including quality of life with their current symptomology), ability to perform good wound care to prevent infection and disease spread, morbidity from a major surgical procedure, as well as oral function or dental rehabilitation after marginal or segmental resection should be considered. Radiographic imaging is of utmost importance in the evaluation of MRONJ lesions. Three-dimensional imaging can identify forming or fully formed sequestra and potentially decrease the invasiveness of a surgical procedure. Maintenance of maxillary or mandibular integrity is desirable, as the reconstruction of surgical defects in this population can be challenging.[63,222]

Stage 1 patients can be managed with chlorhexidine wound care and improved oral hygiene to remove the biofilm from the necrotic bone surface.[63] Surgery may not be indicated in the absence of disease progression, with patient adequate quality of life.[63,223] Stage 2 patients may struggle with local wound care and may require antibiotics for symptom control. Those patients who remain refractory to nonoperative treatment or those patients who cannot maintain adequate hygiene may benefit from operative therapy. In the presence of developing or established bony

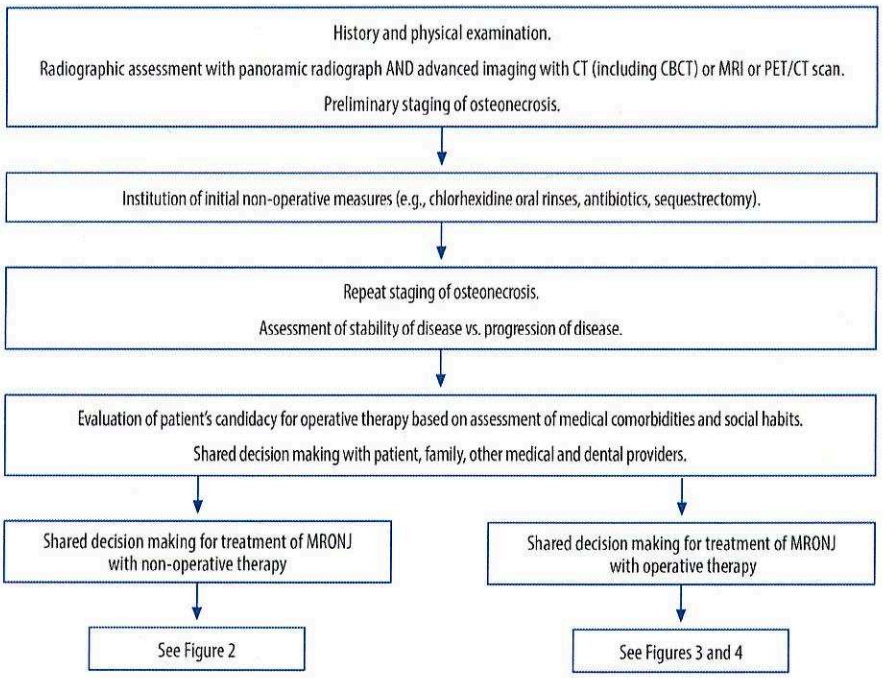

FIGURE 1. Initial evaluation.

Ruggiero et al. AAOMS' Position Paper on MRONJ—2022 Update. J Oral Maxillofac Surg 2022.

sequestra, nonoperative therapy may be indicated to allow for ultimate sequestrectomy. Exfoliation of the exposed, necrotic bone will often result in disease resolution.[63,224,225] Therefore, for those patients with Stage 2 or 3 diseases who are poor surgical candidates, nonoperative therapies may be indicated (Fig 2).

There is little evidence to suggest that the use of adjunctive therapies, such as hyperbaric oxygen or

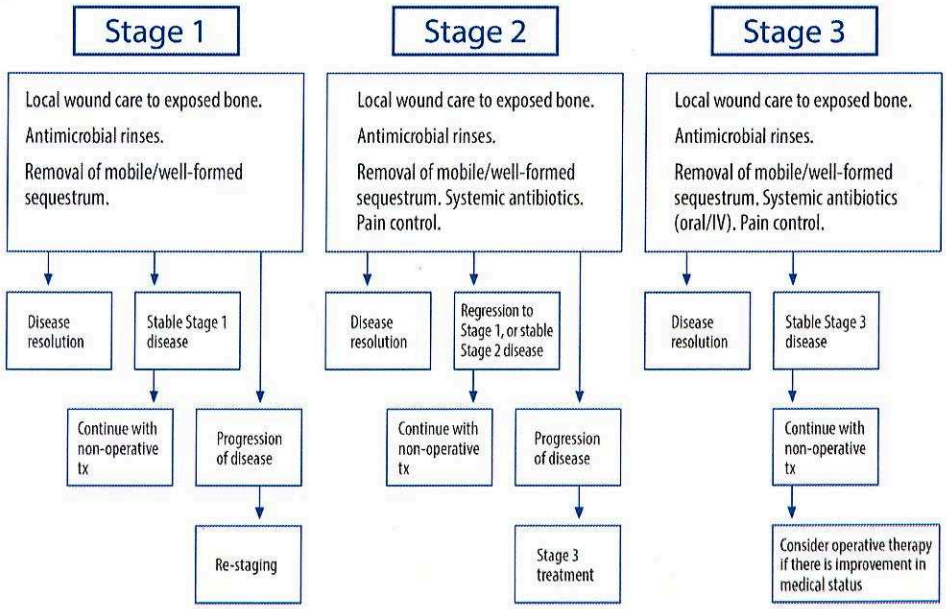

FIGURE 2. Non-operative therapies.

Ruggiero et al. AAOMS' Position Paper on MRONJ—2022 Update. J Oral Maxillofac Surg 2022.

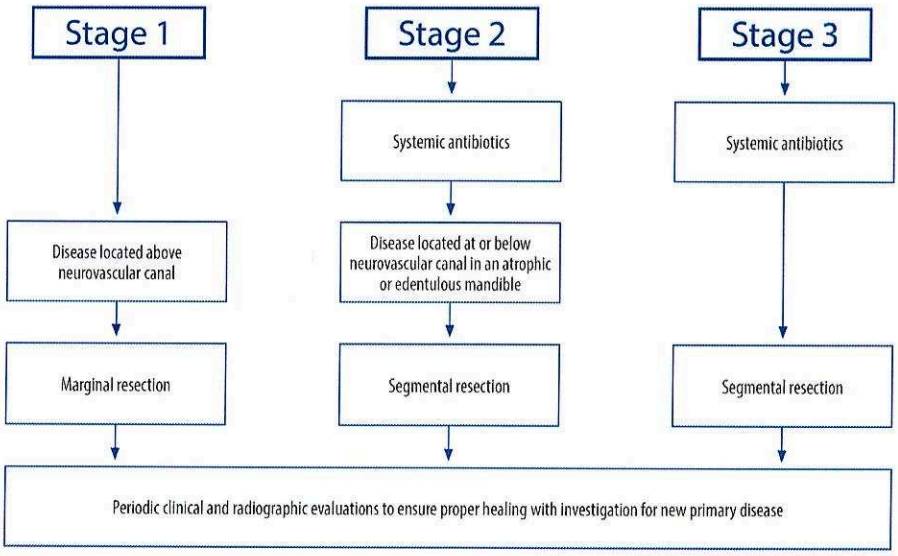

FIGURE 3. Operative therapies for mandibular disease.

Ruggiero et al. AAOMS' Position Paper on MRONJ—2022 Update. J Oral Maxillofac Surg 2022.

ozone therapy, can lead to MRONJ resolution. Larger studies and controlled trials have yet to demonstrate the efficacy of the aforementioned treatments.[226-229] Therefore, these therapies should not be recommended as a mainstay of treatment at this time.

The use of vitamin E and pentoxifylline as an adjunct to standard MRONJ therapies have been reported only in case studies. A randomized, prospective, placebo-controlled trial of vitamin E and pentoxifylline is underway and will provide additional information about this treatment modality. Teriparatide, one of the few anabolic agents used for the treatment of osteoporosis, also has shown promise as an adjunct for the treatment of MRONJ in osteoporotic patients.[230]

Operative therapy

While nonoperative therapy continues to be a treatment option for MRONJ, operative therapy is increasingly reported as a viable option with high success rates for all stages of the disease (Figs 3 and 4).

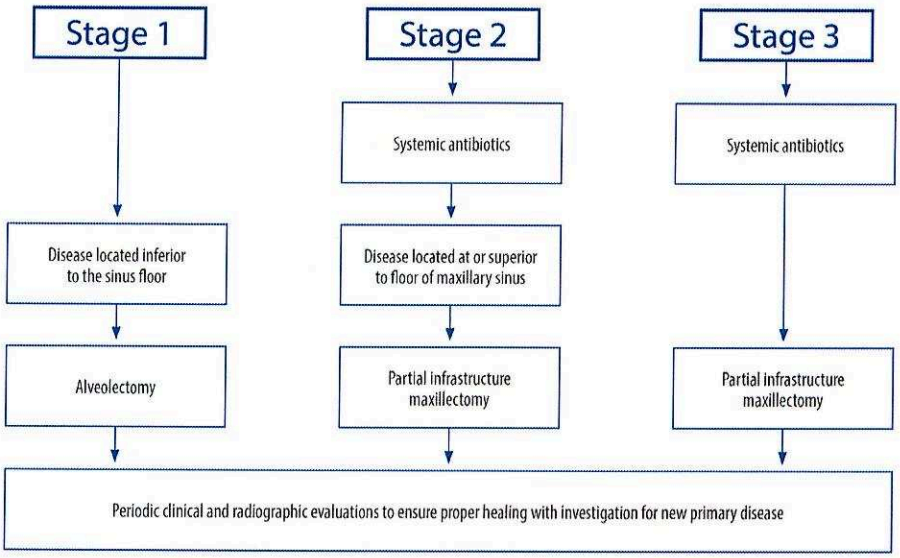

FIGURE 4. Operative therapies for maxillary disease.

Ruggiero et al. AAOMS' Position Paper on MRONJ—2022 Update. J Oral Maxillofac Surg 2022.

Numerous reports have identified high success rates associated with resection of MRONJ lesions.[231-237] Importantly, one must consider that MRONJ may progress over time, albeit in an unpredictable manner.[238] Furthermore, adopting a nonoperative approach to MRONJ does not uniformly result in sequestration of the exposed necrotic bone with disease resolution.[239] Thus, operative intervention should be explored and presented as a treatment option in an attempt to reduce the progression of disease with the recognition that early surgical intervention can predict beneficial patient outcomes.[240]

Segmental or marginal resection of the mandible and partial maxillectomy are effective methods to control MRONJ.[231-238,241] This approach can be applied to patients with all stages of MRONJ, including Stage 1 disease.[169] These resections require margins beyond the borders of the necrotic bone to an area of vital, bleeding bone. Additional reports have identified success when surgical resection of MRONJ was performed by experienced surgeons.[242,243] Consistent with surgical principles, control of comorbid conditions is paramount in managing MRONJ.[241] Physiologically compromised patients, such as those with an increasing burden of distant metastatic disease, may not respond favorably to resection of their osteonecrotic jaw, and may occasionally develop refractory disease.[241] Finally, surgical resection for MRONJ in patients with metastatic cancer may identify metastases in the jaw specimen, albeit in a minority of patients.[62]

Active clinical and radiographic surveillance is critical in the nonoperative management of patients with Stage 1, 2, and 3 diseases to monitor for signs of disease progression. In patients who demonstrate the failure of nonoperative therapy, early operative intervention is recommended. In patients with a progressive clinical or radiographic disease or more advanced disease at presentation, surgical resection of MRONJ should be performed without first instituting prolonged nonoperative measures. MRONJ represents a complex wound whereby operative therapy can be performed in a timely fashion.[241,244] Although controversy between operative and nonoperative therapies exist, operative treatment of patients has demonstrated maintenance of mucosal coverage, improved quality of life, and expedient resumption of antiresorptive therapy for all stages of MRONJ disease.[245] The benefit of drug holidays for the operative intervention of MRONJ has not been substantiated.

Future Research

AAOMS realizes that MRONJ is a complex disease process with a multifactorial etiology for which many questions remain unanswered. Continued preclinical and clinical data are required, especially in the form of prospective studies. Continued research efforts and the outcomes that result should be considered the foundation upon which recommendations are developed that will guide patients and providers. While the data supporting the conclusion that antiresorptives represent genuine risk factors are robust, this is not the case for other classifications of medications (eg, antiangiogenics, corticosteroids, immune modulators). Published studies have reported a relationship of certain dosing practices (eg, transition from BPs to DMB) or a synergistic effect between antiresorptive medications and antiangiogenic medication with a risk of MRONJ. These associations, however, are based on case reports and small case series. It also has been hypothesized that the total exposure to an antiresorptive medication is a risk factor for developing MRONJ. However, this has been difficult to demonstrate, possibly as a result of not having a good measure of exposure other than years of treatment. Similar to the cancer risk associated with tobacco use (eg, pack/years), the antiresorptive exposure risk MRONJ may be better defined as a cumulative dose load (eg, mg equivalent of BP/years of exposure) that would account for risk associated with different medications and dosing schedules over time. Dose-reduction protocols and individualized strategies for antiresorptive therapy in long-term cancer survivors with a metastatic bone disease are being explored. It remains to be determined if these protocols will reduce the risk of MRONJ in this patient cohort.[246] AAOMS acknowledges the challenge of elucidating potential risks associated with non-antiresorptive therapies, alone or in combination with antiresorptive medications, and therefore considers it imperative that research efforts continue in the form of prospective studies.

A review of the current literature also failed to provide sound data in the form of randomized, controlled trials that would establish the effectiveness of biomarkers and drug holidays or validate a risk relationship with genetic markers and MRONJ. Until these relationships are established or refuted, AAOMS considers it prudent to recognize that these factors may play a role in the development and management of MRONJ.

References

1. Advisory task Force on bisphosphonate-related Ostenonecrosis of the jaws AAoO, maxillofacial S: American association of oral and maxillofacial surgeons position paper on bisphosphonate-related osteonecrosis of the jaws. J Oral Maxillofac Surg 65:369, 2007
2. Ruggiero SL, Dodson TB, Assael LA, et al: Task Force on bisphosphonate-related osteonecrosis of the jaws AAoO, maxillofacial S: American association of oral and maxillofacial surgeons position paper on bisphosphonate-related osteonecrosis of the jaw - 2009 update. Aust Endod J 35:119, 2009

3. Ruggiero SL, Dodson TB, Fantasia J, et al: American Association of Oral and Maxillofacial Surgeons position paper on medication-related osteonecrosis of the jaw–2014 update. J Oral Maxillofac Surg 72:1938, 2014
4. Saad F, Gleason DM, Murray R, et al: Zoledronic acid prostate cancer study G: A randomized, placebo-controlled trial of zoledronic acid in patients with hormone-refractory metastatic prostate carcinoma. J Natl Cancer Inst 94:1458, 2002
5. Saad F, Brown JE, Van Poznak C, et al: Incidence, risk factors, and outcomes of osteonecrosis of the jaw: Integrated analysis from three blinded active-controlled phase III trials in cancer patients with bone metastases. Ann Oncol 23:1341, 2012
6. Rosen LS, Gordon D, Tchekmedyian S, et al: Zoledronic acid versus placebo in the treatment of skeletal metastases in patients with lung cancer and other solid tumors: A phase III, double-blind, randomized trial–the zoledronic acid lung cancer and other solid tumors study group. J Clin Oncol 21:3150, 2003
7. Hortobagyi GN, Theriault RL, Porter L, et al: Efficacy of pamidronate in reducing skeletal complications in patients with breast cancer and lytic bone metastases. Protocol 19 Aredia Breast Cancer Study Group. N Engl J Med 335:1785, 1996
8. Hortobagyi GN, Theriault RL, Lipton A, et al: Long-term prevention of skeletal complications of metastatic breast cancer with pamidronate. Protocol 19 Aredia Breast Cancer Study Group. J Clin Oncol 16:2038, 1998
9. Berenson JR, Lichtenstein A, Porter L, et al: Efficacy of pamidronate in reducing skeletal events in patients with advanced multiple myeloma. Myeloma Aredia Study Group. N Engl J Med 334:488, 1996
10. Berenson JR, Lichtenstein A, Porter L, et al: Long-term pamidronate treatment of advanced multiple myeloma patients reduces skeletal events. Myeloma Aredia Study Group. J Clin Oncol 16:593, 1998
11. Berenson JR, Hillner BE, Kyle RA, et al: American society of clinical oncology bisphosphonates Expert P: American society of clinical oncology clinical practice guidelines: The role of bisphosphonates in multiple myeloma. J Clin Oncol 20:3719, 2002
12. Stopeck A, Brufsky A, Kennedy L, et al: Cost-effectiveness of denosumab for the prevention of skeletal-related events in patients with solid tumors and bone metastases in the United States. J Med Econ 23:37, 2020
13. Jeon HL, Oh IS, Baek YH, et al: Zoledronic acid and skeletal-related events in patients with bone metastatic cancer or multiple myeloma. J Bone Miner Metab 38:254, 2020
14. Delmas PD: The use of bisphosphonates in the treatment of osteoporosis. Curr Opin Rheumatol 17:462, 2005
15. Watts NB: Bisphosphonate treatment of osteoporosis. Clin Geriatr Med 19:395, 2003
16. Gossiel F, Paggiosi MA, Naylor KE, et al: The effect of bisphosphonates on bone turnover and bone balance in postmenopausal women with osteoporosis: The T-score bone marker approach in the TRIO study. Bone 131:115158, 2020
17. Black DM, Cummings SR, Karpf DB, et al: Randomised trial of effect of alendronate on risk of fracture in women with existing vertebral fractures. Fracture Intervention Trial Research Group. Lancet 348:1535, 1996
18. Black DM, Delmas PD, Eastell R, et al: Once-yearly zoledronic acid for treatment of postmenopausal osteoporosis. N Engl J Med 356:1809, 2007
19. Nakamura T, Fukunaga M, Nakano T, et al: Efficacy and safety of once-yearly zoledronic acid in Japanese patients with primary osteoporosis: Two-year results from a randomized placebo-controlled double-blind study (ZOledroNate treatment in efficacy to osteoporosis; ZONE study). Osteoporos Int 28:389, 2017
20. Cranney A, Wells G, Willan A, et al: Osteoporosis Methodology G, the Osteoporosis Research Advisory G: Meta-analyses of therapies for postmenopausal osteoporosis. II. Meta-analysis of alendronate for the treatment of postmenopausal women. Endocr Rev 23:508, 2002
21. Delmas PD, Meunier PJ: The management of Paget's disease of bone. N Engl J Med 336:558, 1997
22. Letocha AD, Cintas HL, Troendle JF, et al: Controlled trial of pamidronate in children with types III and IV osteogenesis imperfecta confirms vertebral gains but not short-term functional improvement. J Bone Miner Res 20:977, 2005
23. Florenzano P, Pan KS, Brown SM, et al: Age-related changes and effects of bisphosphonates on bone turnover and disease progression in fibrous dysplasia of bone. J Bone Miner Res 34:653, 2019
24. Boyce AM, Kelly MH, Brillante BA, et al: A randomized, double blind, placebo-controlled trial of alendronate treatment for fibrous dysplasia of bone. J Clin Endocrinol Metab 99:4133, 2014
25. Cummings SR, San Martin J, McClung MR, et al: Denosumab for prevention of fractures in postmenopausal women with osteoporosis. N Engl J Med 361:756, 2009
26. Papapoulos S, Chapurlat R, Libanati C, et al: Five years of denosumab exposure in women with postmenopausal osteoporosis: Results from the first two years of the FREEDOM extension. J Bone Miner Res 27:694, 2012
27. Kanis JA, Harvey NC, Lorentzon M, et al: Combining fracture outcomes in phase 3 trials of osteoporosis: An analysis of the effects of denosumab in postmenopausal women. Osteoporos Int 32:165, 2021
28. Miller PD, Pannacciulli N, Malouf-Sierra J, et al: Efficacy and safety of denosumab vs. bisphosphonates in postmenopausal women previously treated with oral bisphosphonates. Osteoporos Int 31:181, 2020
29. Terpos E, Raje N, Croucher P, et al: Denosumab compared with zoledronic acid on PFS in multiple myeloma: Exploratory results of an international phase 3 study. Blood Adv 5:725, 2021
30. Fizazi K, Carducci M, Smith M, et al: Denosumab versus zoledronic acid for treatment of bone metastases in men with castration-resistant prostate cancer: A randomised, double-blind study. Lancet 377:813, 2011
31. Stopeck AT, Lipton A, Body JJ, et al: Denosumab compared with zoledronic acid for the treatment of bone metastases in patients with advanced breast cancer: A randomized, double-blind study. J Clin Oncol 28:5132, 2010
32. Chawla S, Henshaw R, Seeger L, et al: Safety and efficacy of denosumab for adults and skeletally mature adolescents with giant cell tumour of bone: Interim analysis of an open-label, parallel-group, phase 2 study. Lancet Oncol 14:901, 2013
33. Bredell M, Rordorf T, Kroiss S, et al: Denosumab as a treatment alternative for central giant cell Granuloma: A long-term retrospective cohort study. J Oral Maxillofac Surg 76:775, 2018
34. Boyce AM: Denosumab: An emerging therapy in pediatric bone Disorders. Curr Osteoporos Rep 15:283, 2017
35. de Castro LF, Burke AB, Wang HD, et al: Activation of RANK/RANKL/OPG pathway is involved in the pathophysiology of fibrous dysplasia and associated with disease burden. J Bone Miner Res 34:290, 2019
36. Palmisano B, Spica E, Remoli C, et al: RANKL inhibition in fibrous dysplasia of bone: A preclinical study in a mouse model of the human disease. J Bone Miner Res 34:2171, 2019
37. Saag KG, Petersen J, Brandi ML, et al: Romosozumab or alendronate for fracture prevention in women with osteoporosis. N Engl J Med 377:1417, 2017
38. Campisi G, Mauceri R, Bertoldo F, et al: Medication-related osteonecrosis of jaws (MRONJ) prevention and diagnosis: Italian consensus update 2020. Int J Environ Res Public Health 17, 2020
39. Steinberg ME, Hayken GD, Steinberg DR: A quantitative system for staging avascular necrosis. J Bone Joint Surg Br 77:34, 1995
40. Fleisher KE, Welch G, Kottal S, et al: Predicting risk for bisphosphonate-related osteonecrosis of the jaws: CTX versus radiographic markers. Oral Surg Oral Med Oral Pathol Oral Radiol Endod 110:509, 2010
41. Fedele S, Porter SR, D'Aiuto F, et al: Nonexposed variant of bisphosphonate-associated osteonecrosis of the jaw: A case series. Am J Med 123:1060, 2010
42. Fleisher KE, Janal MN, Albstein N, et al: Comorbid conditions are a risk for osteonecrosis of the jaw unrelated to antiresorptive therapy. Oral Surg Oral Med Oral Pathol Oral Radiol 127: 140, 2019

43. Farah CS, Savage NW: Oral ulceration with bone sequestration. Aust Dent J 48:61, 2003
44. Filippi A, Dreyer T, Bohle RM, et al: Sequestration of the alveolar bone by invasive aspergillosis in acute myeloid leukemia. J Oral Pathol Med 26:437, 1997
45. Friel P, Macintyre DR: Bone sequestration from lower 3rd molar region. Br Dent J 193:366, 2002
46. Huang JS, Kok SH, Lee JJ, et al: Extensive maxillary sequestration resulting from mucormycosis. Br J Oral Maxillofac Surg 43:532, 2005
47. Peters E, Daley T, American Academy of Oral and Maxillofacial Pathology. Persistent painful ulcer of the posterior lingual mandibular mucosa. J Contemp Dent Pract 4:71, 2003
48. Sonnier KE, Horning GM: Spontaneous bony exposure: A report of 4 cases of idiopathic exposure and sequestration of alveolar bone. J Periodontol 68:758, 1997
49. Peters E, Lovas GL, Wysocki GP: Lingual mandibular sequestration and ulceration. Oral Surg Oral Med Oral Pathol 75:739, 1993
50. Nandakumar H, Shankaramba KB: Massive sequestration of the upper jaw: A case report. Br J Oral Maxillofac Surg 28(55), 1990
51. Ramon Y, Oberman M, Horowitz I, Freedman A: Extensive maxillary sequestration resulting from rhinocerebral mucormyocosis. J Oral Surg 35:989, 1977
52. Liao MT, Chien WC, Wang JC, et al: Increased risk of bisphosphonate-related osteonecrosis of the jaw in patients with Sjogren's syndrome: Nationwide population-based cohort study. BMJ Open 9:e024655, 2019
53. Schwartz HC: Osteonecrosis of the jaws: A complication of cancer chemotherapy. Head Neck Surg 4:251, 1982
54. Cooper JC: Tooth exfoliation and osteonecrosis of the jaw following herpes zoster. Br Dent J 143:297, 1977
55. Schwartz O, Kvorning SA: Tooth exfoliation, osteonecrosis of the jaw and neuralgia following herpes zoster of the trigeminal nerve. Int J Oral Surg 11:364, 1982
56. Calhoun KH, Shapiro RD, Stiernberg CM, et al: Osteomyelitis of the mandible. Arch Otolaryngol Head Neck Surg 114:1157, 1988
57. Koorbusch GF, Fotos P, Goll KT: Retrospective assessment of osteomyelitis. Etiology, demographics, risk factors, and management in 35 cases. Oral Surg Oral Med Oral Pathol 74:149, 1992
58. Maines E, Monti E, Doro F, et al: Children and adolescents treated with neridronate for osteogenesis imperfecta show no evidence of any osteonecrosis of the jaw. J Bone Miner Metab 30:434, 2012
59. Black DM, Schwartz AV, Ensrud KE, et al: Effects of continuing or stopping alendronate after 5 years of treatment: The fracture intervention trial long-term extension (FLEX): A randomized trial. JAMA 296:2927, 2006
60. Black DM, Reid IR, Boonen S, et al: The effect of 3 versus 6 years of zoledronic acid treatment of osteoporosis: A randomized extension to the HORIZON-Pivotal fracture trial (PFT). J Bone Miner Res 27:243, 2012
61. Black DM, Reid IR, Cauley JA, et al: The effect of 6 versus 9 years of zoledronic acid treatment in osteoporosis: A randomized second extension to the HORIZON-Pivotal fracture trial (PFT). J Bone Miner Res 30:934, 2015
62. Carlson ER, Fleisher KE, Ruggiero SL: Metastatic cancer identified in osteonecrosis specimens of the jaws in patients receiving intravenous bisphosphonate medications. J Oral Maxillofac Surg 71:2077, 2013
63. Hadaya D, Soundia A, Freymiller E, et al: Nonsurgical management of medication-related osteonecrosis of the jaws using local wound care. J Oral Maxillofac Surg 76:2332, 2018
64. Marx RE, Sawatari Y, Fortin M, Broumand V: Bisphosphonate-induced exposed bone (osteonecrosis/osteopetrosis) of the jaws: Risk factors, recognition, prevention, and treatment. J Oral Maxillofac Surg 63:1567, 2005
65. Aghaloo T, Hazboun R, Tetradis S: Pathophysiology of osteonecrosis of the jaws. Oral Maxillofac Surg Clin North Am 27:489, 2015
66. Johnston CB, Dagar M: Osteoporosis in older adults. Med Clin North Am 104:873, 2020
67. Black DM, Rosen CJ: Clinical practice. Postmenopausal Osteoporos N Engl J Med 374:254, 2016
68. Schwartz E, Reichert Z, Van Poznak C: Pharmacologic management of metastatic bone disease. Bone 115735, 2020
69. Coleman R: Bisphosphonates and breast cancer - from cautious palliation to saving lives. Bone 140:115570, 2020
70. Lacey DL, Boyle WJ, Simonet WS, et al: Bench to bedside: Elucidation of the OPG-RANK-RANKL pathway and the development of denosumab. Nat Rev Drug Discov 11:401, 2012
71. Coleman RE, Major P, Lipton A, et al: Predictive value of bone resorption and formation markers in cancer patients with bone metastases receiving the bisphosphonate zoledronic acid. J Clin Oncol 23:4925, 2005
72. Stewart AF: Clinical practice. Hypercalcemia associated with cancer. N Engl J Med 352:373, 2005
73. Benjamin B, Benjamin MA, Swe M, Sugathan S: Review on the comparison of effectiveness between denosumab and bisphosphonates in post-menopausal osteoporosis. Osteoporos Sarcopenia 2:77, 2016
74. Limones A, Saez-Alcaide LM, Diaz-Parreno SA, et al: Medication-related osteonecrosis of the jaws (MRONJ) in cancer patients treated with denosumab VS. Zoledronic acid: A systematic review and meta-analysis. Med Oral Patol Oral Cir Bucal 25: e326, 2020
75. Hallmer F, Andersson G, Gotrick B, et al: Prevalence, initiating factor, and treatment outcome of medication-related osteonecrosis of the jaw-a 4-year prospective study. Oral Surg Oral Med Oral Pathol Oral Radiol 126:477, 2018
76. Soundia A, Hadaya D, Esfandi N, et al: Osteonecrosis of the jaws (ONJ) in mice after extraction of teeth with periradicular disease. Bone 90:133, 2016
77. Wehrhan F, Gross C, Creutzburg K, et al: Osteoclastic expression of higher-level regulators NFATc1 and BCL6 in medication-related osteonecrosis of the jaw secondary to bisphosphonate therapy: A comparison with osteoradionecrosis and osteomyelitis. J Transl Med 17:69, 2019
78. de Molon RS, Shimamoto H, Bezouglaia O, et al: OPG-fc but not zoledronic acid discontinuation Reverses osteonecrosis of the jaws (ONJ) in mice. J Bone Miner Res 30:1627, 2015
79. Hadaya D, Soundia A, Gkouveris I, et al: Antiresorptive-type and discontinuation-timing Affect ONJ burden. J Dent Res 100:746, 2021
80. Kuroshima S, Entezami P, McCauley LK, Yamashita J: Early effects of parathyroid hormone on bisphosphonate/steroid-associated compromised osseous wound healing. Osteoporos Int 25:1141, 2014
81. Dayisoylu EH, Senel FC, Ungor C, et al: The effects of adjunctive parathyroid hormone injection on bisphosphonate-related osteonecrosis of the jaws: An animal study. Int J Oral Maxillofac Surg 42:1475, 2013
82. Chopra K, Malhan N: Teriparatide for the treatment of medication-related osteonecrosis of the jaw. Am J Ther 28: e469, 2020
83. Ficarra G, Beninati F, Rubino I, et al: Osteonecrosis of the jaws in periodontal patients with a history of bisphosphonates treatment. J Clin Periodontol 32:1123, 2005
84. Thumbigere-Math V, Michalowicz BS, Hodges JS, et al: Periodontal disease as a risk factor for bisphosphonate-related osteonecrosis of the jaw. J Periodontol 85:226, 2014
85. Aghaloo TL, Kang B, Sung EC, et al: Periodontal disease and bisphosphonates induce osteonecrosis of the jaws in the rat. J Bone Miner Res 26:1871, 2011
86. Kang B, Cheong S, Chaichanasakul T, et al: Periapical disease and bisphosphonates induce osteonecrosis of the jaws in mice. J Bone Miner Res 28:1631, 2013
87. Hadaya D, Soundia A, Gkouveris I, et al: Development of medication-related osteonecrosis of the jaw after extraction of teeth with experimental periapical disease. J Oral Maxillofac Surg 77:71, 2019
88. Aguirre JI, Akhter MP, Kimmel DB, et al: Oncologic doses of zoledronic acid induce osteonecrosis of the jaw-like lesions in rice rats (Oryzomys palustris) with periodontitis. J Bone Miner Res 27:2130, 2012

89. Soma T, Iwasaki R, Sato Y, et al: Tooth extraction in mice administered zoledronate increases inflammatory cytokine levels and promotes osteonecrosis of the jaw. J Bone Miner Metab 39:372, 2021
90. de Molon RS, Hsu C, Bezouglaia O, et al: Rheumatoid arthritis Exacerbates the severity of osteonecrosis of the jaws (ONJ) in mice. A randomized, prospective, controlled animal study. J Bone Miner Res 31:1596, 2016
91. Kim T, Kim S, Song M, et al: Removal of pre-existing periodontal inflammatory condition before tooth extraction Ameliorates medication-related osteonecrosis of the jaw-like lesion in mice. Am J Pathol 188:2318, 2018
92. Kuroshima S, Nakajima K, Sasaki M, et al: Systemic administration of quality- and quantity-controlled PBMNCs reduces bisphosphonate-related osteonecrosis of jaw-like lesions in mice. Stem Cell Res Ther 10:209, 2019
93. Hansen T, Kunkel M, Weber A, James Kirkpatrick C: Osteonecrosis of the jaws in patients treated with bisphosphonates - histomorphologic analysis in comparison with infected osteoradionecrosis. J Oral Pathol Med 35:155, 2006
94. Mawardi H, Giro G, Kajiya M, et al: A role of oral bacteria in bisphosphonate-induced osteonecrosis of the jaw. J Dent Res 90:1339, 2011
95. Vandone AM, Donadio M, Mozzati M, et al: Impact of dental care in the prevention of bisphosphonate-associated osteonecrosis of the jaw: A single-center clinical experience. Ann Oncol 23:193, 2012
96. Sedghizadeh PP, Kumar SK, Gorur A, et al: Microbial biofilms in osteomyelitis of the jaw and osteonecrosis of the jaw secondary to bisphosphonate therapy. J Am Dent Assoc 140:1259, 2009
97. Francini F, Pascucci A, Francini E, et al: Osteonecrosis of the jaw in patients with cancer who received zoledronic acid and bevacizumab. J Am Dent Assoc 142:506, 2011
98. Migliorati CA, Schubert MM, Peterson DE, Seneda LM: Bisphosphonate-associated osteonecrosis of mandibular and maxillary bone: An emerging oral complication of supportive cancer therapy. Cancer 104:83, 2005
99. Petek D, Hannouche D, Suva D: Osteonecrosis of the femoral head: Pathophysiology and current concepts of treatment. EFORT Open Rev 4:85, 2019
100. Wood J, Bonjean K, Ruetz S, et al: Novel antiangiogenic effects of the bisphosphonate compound zoledronic acid. J Pharmacol Exp Ther 302:1055, 2002
101. Santini D, Vincenzi B, Dicuonzo G, et al: Zoledronic acid induces significant and long-lasting modifications of circulating angiogenic factors in cancer patients. Clin Cancer Res 9: 2893, 2003
102. Ishtiaq S, Edwards S, Sankaralingam A, et al: The effect of nitrogen containing bisphosphonates, zoledronate and alendronate, on the production of pro-angiogenic factors by osteoblastic cells. Cytokine 71:154, 2015
103. Kun-Darbois JD, Libouban H, Mabilleau G, et al: Bone mineralization and vascularization in bisphosphonate-related osteonecrosis of the jaw: An experimental study in the rat. Clin Oral Investig 22:2997, 2018
104. Gao SY, Lin RB, Huang SH, et al: PDGF-BB exhibited therapeutic effects on rat model of bisphosphonate-related osteonecrosis of the jaw by enhancing angiogenesis and osteogenesis. Bone 144:115117, 2021
105. Bi Y, Gao Y, Ehirchiou D, et al: Bisphosphonates cause osteonecrosis of the jaw-like disease in mice. Am J Pathol 177:280, 2010
106. Gkouveris I, Hadaya D, Soundia A, et al: Vasculature submucosal changes at early stages of osteonecrosis of the jaw (ONJ). Bone 123:234, 2019
107. Vallina C, Ramirez L, Torres J, et al: Osteonecrosis of the jaws produced by sunitinib: A systematic review. Med Oral Patol Oral Cir Bucal 24:e326, 2019
108. Gacche RN, Meshram RJ: Angiogenic factors as potential drug target: Efficacy and limitations of anti-angiogenic therapy. Biochim Biophys Acta 161:2014, 1846
109. Akita Y, Kuroshima S, Nakajima K, et al: Effect of anti-angiogenesis induced by chemotherapeutic monotherapy, chemotherapeutic/bisphosphonate combination therapy and anti-VEGFA mAb therapy on tooth extraction socket healing in mice. J Bone Miner Metab 36:547, 2018
110. Rugani P, Walter C, Kirnbauer B, et al: Prevalence of medication-related osteonecrosis of the jaw in patients with breast cancer, prostate cancer, and multiple myeloma. Dent J (Basel) 4, 2016
111. Dimopoulos MA, Kastritis E, Anagnostopoulos A, et al: Osteonecrosis of the jaw in patients with multiple myeloma treated with bisphosphonates: Evidence of increased risk after treatment with zoledronic acid. Haematologica 91:968, 2006
112. Badros A, Weikel D, Salama A, et al: Osteonecrosis of the jaw in multiple myeloma patients: Clinical features and risk factors. J Clin Oncol 24:945, 2006
113. Raje N, Terpos E, Willenbacher W, et al: Denosumab versus zoledronic acid in bone disease treatment of newly diagnosed multiple myeloma: An international, double-blind, double-dummy, randomised, controlled, phase 3 study. Lancet Oncol 19:370, 2018
114. Filleul O, Crompot E, Saussez S: Bisphosphonate-induced osteonecrosis of the jaw: A review of 2,400 patient cases. J Cancer Res Clin Oncol 136:1117, 2010
115. Bastos P, Patel V, Festy F, et al: In-vivo imaging of the microvasculature of the soft tissue margins of osteonecrotic jaw lesions. Br Dent J 223:699, 2017
116. Zhang Q, Yu W, Lee S, et al: Bisphosphonate induces osteonecrosis of the jaw in diabetic mice via NLRP3/Caspase-1-Dependent IL-1beta mechanism. J Bone Miner Res 30:2300, 2015
117. Kabilova TO, Kovtonyuk LV, Zonov EV, et al: Immunotherapy of hepatocellular carcinoma with small double-stranded RNA. BMC Cancer 14:338, 2014
118. Hayano H, Kuroshima S, Sasaki M, et al: Distinct immunopathology in the early stages between different antiresorptives-related osteonecrosis of the jaw-like lesions in mice. Bone 135:115308, 2020
119. Rao NJ, Yu RQ, Wang JY, et al: Effect of periapical diseases in development of MRONJ in immunocompromised mouse model. Biomed Res Int 2019:1271492, 2019
120. Aghaloo TL, Tetradis S: Osteonecrosis of the jaw in the absence of antiresorptive or antiangiogenic exposure: A series of 6 cases. J Oral Maxillofac Surg 75:129, 2017
121. Bamias A, Kastritis E, Bamia C, et al: Osteonecrosis of the jaw in cancer after treatment with bisphosphonates: Incidence and risk factors. J Clin Oncol 23:8580, 2005
122. Qu X, Wang Z, Zhou T, Shan L: Determination of the molecular mechanism by which macrophages and gammadelta-T cells contribute to ZOL-induced ONJ. Aging (Albany NY) 12: 20743, 2020
123. Rodriguez-Lozano FJ, Onate-Sanchez R, Gonzalvez-Garcia M, et al: Allogeneic bone marrow mesenchymal stem cell transplantation in tooth extractions sites Ameliorates the incidence of osteonecrotic jaw-like lesions in zoledronic acid-treated rats. J Clin Med 9, 2020
124. Alonso-Rodriguez E, Gonzalez-Martin-Moro J, Cebrian-Carretero JL, et al: Bisphosphonate-related osteonecrosis. Application of adipose-derived stem cells in an experimental murine model. Med Oral Patol Oral Cir Bucal 24: e529, 2019
125. Barba-Recreo P, Del Castillo Pardo de Vera JL, Georgiev-Hristov T, et al: Adipose-derived stem cells and platelet-rich plasma for preventive treatment of bisphosphonate-related osteonecrosis of the jaw in a murine model. J Craniomaxillofac Surg 43:1161, 2015
126. Sarasquete ME, Garcia-Sanz R, Marin L, et al: Bisphosphonate-related osteonecrosis of the jaw is associated with polymorphisms of the cytochrome P450 CYP2C8 in multiple myeloma: A genome-wide single nucleotide polymorphism analysis. Blood 112:2709, 2008
127. Yang G, Hamadeh IS, Katz J, et al: SIRT1/HERC4 Locus associated with bisphosphonate-induced osteonecrosis of the jaw: An Exome-wide association analysis. J Bone Miner Res 33:91, 2018

128. Yang G, Collins JM, Rafiee R, et al: SIRT1 gene SNP rs932658 is associated with medication-related osteonecrosis of the jaw. J Bone Miner Res 36:347, 2021
129. Lee KH, Kim SH, Kim CH, et al: Identifying genetic variants underlying medication-induced osteonecrosis of the jaw in cancer and osteoporosis: A case control study. J Transl Med 17: 381, 2019
130. Kastritis E, Melea P, Bagratuni T, et al: Genetic factors related with early onset of osteonecrosis of the jaw in patients with multiple myeloma under zoledronic acid therapy. Leuk Lymphoma 58:2304, 2017
131. Guo Z, Cui W, Que L, et al: Pharmacogenetics of medication-related osteonecrosis of the jaw: A systematic review and meta-analysis. Int J Oral Maxillofac Surg 49:298, 2020
132. Valachis A, Polyzos NP, Coleman RE, et al: Adjuvant therapy with zoledronic acid in patients with breast cancer: A systematic review and meta-analysis. Oncologist 18:353, 2013
133. Coleman R, Cameron D, Dodwell D, et al: Adjuvant zoledronic acid in patients with early breast cancer: Final efficacy analysis of the AZURE (BIG 01/04) randomised open-label phase 3 trial. Lancet Oncol 15:997, 2014
134. Gnant M, Pfeiler G, Dubsky PC, et al: Austrian B, Colorectal cancer study G: Adjuvant denosumab in breast cancer (ABCSG-18): A multicentre, randomised, double-blind, placebo-controlled trial. Lancet 386:433, 2015
135. Boquete-Castro A, Gomez-Moreno G, Calvo-Guirado JL, et al: Denosumab and osteonecrosis of the jaw. A systematic analysis of events reported in clinical trials. Clin Oral Implants Res 27: 367, 2016
136. Macherey S, Monsef I, Jahn F, et al: Bisphosphonates for advanced prostate cancer. Cochrane Database Syst Rev 12: CD006250, 2017
137. O'Carrigan B, Wong MH, Willson ML, et al: Bisphosphonates and other bone agents for breast cancer. Cochrane Database Syst Rev 10:CD003474, 2017
138. Coleman R, Finkelstein DM, Barrios C, et al: Adjuvant denosumab in early breast cancer (D-CARE): An international, multicentre, randomised, controlled, phase 3 trial. Lancet Oncol 21:60, 2020
139. Barrett-Lee P, Casbard A, Abraham J, et al: Oral ibandronic acid versus intravenous zoledronic acid in treatment of bone metastases from breast cancer: A randomised, open label, non-inferiority phase 3 trial. Lancet Oncol 15:114, 2014
140. Himelstein AL, Foster JC, Khatcheressian JL, et al: Effect of longer-Interval vs standard dosing of zoledronic acid on skeletal events in patients with bone metastases: A randomized clinical trial. JAMA 317:48, 2017
141. Henry D, Vadhan-Raj S, Hirsh V, et al: Delaying skeletal-related events in a randomized phase 3 study of denosumab versus zoledronic acid in patients with advanced cancer: An analysis of data from patients with solid tumors. Support Care Cancer 22: 679, 2014
142. Peddi P, Lopez-Olivo MA, Pratt GF, Suarez-Almazor ME: Denosumab in patients with cancer and skeletal metastases: A systematic review and meta-analysis. Cancer Treat Rev 39: 97, 2013
143. Jackson GH, Morgan GJ, Davies FE, et al: Osteonecrosis of the jaw and renal safety in patients with newly diagnosed multiple myeloma: Medical Research Council Myeloma IX Study results. Br J Haematol 166:109, 2014
144. Wang X, Yang KH, Wanyan P, Tian JH: Comparison of the efficacy and safety of denosumab versus bisphosphonates in breast cancer and bone metastases treatment: A meta-analysis of randomized controlled trials. Oncol Lett 7:2014, 1997
145. Ng TL, Tu MM, Ibrahim MFK, et al: Long-term impact of bone-modifying agents for the treatment of bone metastases: A systematic review. Support Care Cancer 29:925, 2021
146. Fusco V, Santini D, Armento G, et al: Osteonecrosis of jaw beyond antiresorptive (bone-targeted) agents: New horizons in oncology. Expert Opin Drug Saf 15:925, 2016
147. Nicolatou-Galitis O, Kouri M, Papadopoulou E, et al: Osteonecrosis of the jaw related to non-antiresorptive medications: A systematic review. Support Care Cancer 27:383, 2019
148. King R, Tanna N, Patel V: Medication-related osteonecrosis of the jaw unrelated to bisphosphonates and denosumab-a review. Oral Surg Oral Med Oral Pathol Oral Radiol 127:289, 2019
149. Sacco R, Shah S, Leeson R, et al: Osteonecrosis and osteomyelitis of the jaw associated with tumour necrosis factor-alpha (TNF-alpha) inhibitors: A systematic review. Br J Oral Maxillofac Surg 58:25, 2020
150. Grbic JT, Black DM, Lyles KW, et al: The incidence of osteonecrosis of the jaw in patients receiving 5 milligrams of zoledronic acid: Data from the health outcomes and reduced incidence with zoledronic acid once yearly clinical trials program. J Am Dent Assoc 141:1365, 2010
151. Cosman F, Crittenden DB, Adachi JD, et al: Romosozumab treatment in postmenopausal women with osteoporosis. N Engl J Med 375:1532, 2016
152. Administration USFaD. Background Document for Meeting of Advisory Committee for Reproductive Health Drugs and Drug Safety and Risk Managment Advisory Committee. Adelphi, MD, FDA, HHS, 2011
153. Bone HG, Wagman RB, Brandi ML, et al: 10 years of denosumab treatment in postmenopausal women with osteoporosis: Results from the phase 3 randomised FREEDOM trial and open-label extension. Lancet Diabetes Endocrinol 5:513, 2017
154. FDA. Briefing Information for the September 9, 2011 Joint Meeting of the Reproductive Health Drugs Advisory Committee and the Drug Safety and Risk Managment Advisory Committee. Adelphi, MD, FDA, HHS, 2011
155. Rutkowski P, Gaston L, Borkowska A, et al: Denosumab treatment of inoperable or locally advanced giant cell tumor of bone - multicenter analysis outside clinical trial. Eur J Surg Oncol 44:1384, 2018
156. Chawla S, Blay JY, Rutkowski P, et al: Denosumab in patients with giant-cell tumour of bone: A multicentre, open-label, phase 2 study. Lancet Oncol 20:1719, 2019
157. Hennedige AA, Jayasinghe J, Khajeh J, Macfarlane TV: Systematic review on the incidence of bisphosphonate related osteonecrosis of the jaw in children diagnosed with osteogenesis imperfecta. J Oral Maxillofac Res 4:e1, 2013
158. Duarte NT, Rech BO, Martins IG, et al: Can children be affected by bisphosphonate-related osteonecrosis of the jaw? A systematic review. Int J Oral Maxillofac Surg 49:183, 2020
159. Lo JC, O'Ryan FS, Gordon NP, et al: Predicting risk of osteonecrosis of the jaw with oral bisphosphonate exposure I: Prevalence of osteonecrosis of the jaw in patients with oral bisphosphonate exposure. J Oral Maxillofac Surg 68:243, 2010
160. Aljohani S, Fliefel R, Ihbe J, et al: What is the effect of antiresorptive drugs (ARDs) on the development of medication-related osteonecrosis of the jaw (MRONJ) in osteoporosis patients: A systematic review. J Craniomaxillofac Surg 45:1493, 2017
161. Shudo A, Kishimoto H, Takaoka K, Noguchi K: Long-term oral bisphosphonates delay healing after tooth extraction: A single institutional prospective study. Osteoporos Int 29:2315, 2018
162. Gaudin E, Seidel L, Bacevic M, et al: Occurrence and risk indicators of medication-related osteonecrosis of the jaw after dental extraction: A systematic review and meta-analysis. J Clin Periodontol 42:922, 2015
163. Watts NB, Grbic JT, Binkley N, et al: Invasive oral procedures and events in postmenopausal women with osteoporosis treated with denosumab for up to 10 Years. J Clin Endocrinol Metab 104:2443, 2019
164. Mozzati M, Arata V, Gallesio G: Tooth extraction in patients on zoledronic acid therapy. Oral Oncol 48:817, 2012
165. Yamazaki T, Yamori M, Ishizaki T, et al: Increased incidence of osteonecrosis of the jaw after tooth extraction in patients treated with bisphosphonates: A cohort study. Int J Oral Maxillofac Surg 41:1397, 2012
166. Scoletta M, Arata V, Arduino PG, et al: Tooth extractions in intravenous bisphosphonate-treated patients: A refined protocol. J Oral Maxillofac Surg 71:994, 2013
167. Bodem JP, Kargus S, Eckstein S, et al: Incidence of bisphosphonate-related osteonecrosis of the jaw in high-risk patients undergoing surgical tooth extraction. J Craniomaxillofac Surg 43:510, 2015

168. McGowan K, McGowan T, Ivanovski S: Risk factors for medication-related osteonecrosis of the jaws: A systematic review. Oral Dis 24:527, 2018
169. Kyrgidis A, Vahtsevanos K, Koloutsos G, et al: Bisphosphonate-related osteonecrosis of the jaws: A case-control study of risk factors in breast cancer patients. J Clin Oncol 26:4634, 2008
170. Vahtsevanos K, Kyrgidis A, Verrou E, et al: Longitudinal cohort study of risk factors in cancer patients of bisphosphonate-related osteonecrosis of the jaw. J Clin Oncol 27:5356, 2009
171. Tsao C, Darby I, Ebeling PR, et al: Oral health risk factors for bisphosphonate-associated jaw osteonecrosis. J Oral Maxillofac Surg 71:1360, 2013
172. Qi WX, Tang LN, He AN, et al: Risk of osteonecrosis of the jaw in cancer patients receiving denosumab: A meta-analysis of seven randomized controlled trials. Int J Clin Oncol 19:403, 2014
173. Ripamonti CI, Maniezzo M, Campa T, et al: Decreased occurrence of osteonecrosis of the jaw after implementation of dental preventive measures in solid tumour patients with bone metastases treated with bisphosphonates. The experience of the National Cancer Institute of Milan. Ann Oncol 20:137, 2009
174. Montefusco V, Gay F, Spina F, et al: Antibiotic prophylaxis before dental procedures may reduce the incidence of osteonecrosis of the jaw in patients with multiple myeloma treated with bisphosphonates. Leuk Lymphoma 49:2156, 2008
175. Bantis A, Zissimopoulos A, Sountoulides P, et al: Bisphosphonate-induced osteonecrosis of the jaw in patients with bone metastatic, hormone-sensitive prostate cancer. Risk factors and prevention strategies. Tumori 97:479, 2011
176. Kunchur R, Goss AN: The oral health status of patients on oral bisphosphonates for osteoporosis. Aust Dent J 53:354, 2008
177. Lodi G, Sardella A, Salis A, et al: Tooth extraction in patients taking intravenous bisphosphonates: A preventive protocol and case series. J Oral Maxillofac Surg 68:107, 2010
178. Mozzati M, Gallesio G, Arata V, et al: Platelet-rich therapies in the treatment of intravenous bisphosphonate-related osteonecrosis of the jaw: A report of 32 cases. Oral Oncol 48:469, 2012
179. Ferlito S, Puzzo S, Liardo C: Preventive protocol for tooth extractions in patients treated with zoledronate: A case series. J Oral Maxillofac Surg 69:e1, 2011
180. Schubert M, Klatte I, Linek W, et al: The saxon bisphosphonate register - therapy and prevention of bisphosphonate-related osteonecrosis of the jaws. Oral Oncol 48:349, 2012
181. Bonacina R, Mariani U, Villa F, Villa A: Preventive strategies and clinical implications for bisphosphonate-related osteonecrosis of the jaw: A review of 282 patients. J Can Dent Assoc 77:b147, 2011
182. Khan AA, Morrison A, Hanley DA, et al: International task Force on osteonecrosis of the J: Diagnosis and management of osteonecrosis of the jaw: A systematic review and international consensus. J Bone Miner Res 30:3, 2015
183. Japanese Allied Committee on Osteonecrosis of the JYoneda T, Hagino H, Sugimoto T, et al: Antiresorptive agent-related osteonecrosis of the jaw: Position paper 2017 of the Japanese Allied Committee on osteonecrosis of the jaw. J Bone Miner Metab 35: 6, 2017
184. Aparecida Cariolatto F, Carelli J, de Campos Moreira T, et al: Recommendations for the prevention of bisphosphonate-related osteonecrosis of the jaw: A systematic review. J Evid Based Dent Pract 18:142, 2018
185. Beth-Tasdogan NH, Mayer B, Hussein H, Zolk O: Interventions for managing medication-related osteonecrosis of the jaw. Cochrane Database Syst Rev 10:CD012432, 2017
186. Mucke T, Deppe H, Hein J, et al: Prevention of bisphosphonate-related osteonecrosis of the jaws in patients with prostate cancer treated with zoledronic acid - a prospective study over 6 years. J Craniomaxillofac Surg 44:1689, 2016
187. Smidt-Hansen T, Folkmar TB, Fode K, et al: Combination of zoledronic Acid and targeted therapy is active but may induce osteonecrosis of the jaw in patients with metastatic renal cell carcinoma. J Oral Maxillofac Surg 71:1532, 2013
188. Sivolella S, Lumachi F, Stellini E, Favero L: Denosumab and anti-angiogenetic drug-related osteonecrosis of the jaw: An uncommon but potentially severe disease. Anticancer Res 33:1793, 2013
189. Patel V, McLeod NM, Rogers SN, Brennan PA: Bisphosphonate osteonecrosis of the jaw–a literature review of UK policies versus international policies on bisphosphonates, risk factors and prevention. Br J Oral Maxillofac Surg 49:251, 2011
190. Hellstein JW, Adler RA, Edwards B, et al: Ristic H, American dental association Council on scientific Affairs Expert Panel on antiresorptive A: Managing the care of patients receiving antiresorptive therapy for prevention and treatment of osteoporosis: Executive summary of recommendations from the American dental association Council on scientific Affairs. J Am Dent Assoc 142:1243, 2011
191. Atalay B, Yalcin S, Emes Y, et al: Bisphosphonate-related osteonecrosis: Laser-assisted surgical treatment or conventional surgery? Lasers Med Sci 26:815, 2011
192. Guarneri V, Miles D, Robert N, et al: Bevacizumab and osteonecrosis of the jaw: Incidence and association with bisphosphonate therapy in three large prospective trials in advanced breast cancer. Breast Cancer Res Treat 122:181, 2010
193. Edwards BJ, Hellstein JW, Jacobsen PL, et al: American dental association Council on scientific Affairs Expert Panel on bisphosphonate-associated osteonecrosis of the J: Updated recommendations for managing the care of patients receiving oral bisphosphonate therapy: An advisory statement from the American dental association Council on scientific Affairs. J Am Dent Assoc 139:1674, 2008
194. de-Freitas NR, Lima LB, de-Moura MB, et al: Bisphosphonate treatment and dental implants: A systematic review. Med Oral Patol Oral Cir Bucal 21:e644, 2016
195. de Molon RS, Cheong S, Bezouglaia O, et al: Spontaneous osteonecrosis of the jaws in the maxilla of mice on antiresorptive treatment: A novel ONJ mouse model. Bone 68:11, 2014
196. Messer JG, Jiron JM, Mendieta Calle JL, et al: Zoledronate treatment duration is linked to bisphosphonate-related osteonecrosis of the jaw prevalence in rice rats with generalized periodontitis. Oral Dis 25:1116, 2019
197. Hinchy NV, Jayaprakash V, Rossitto RA, et al: Osteonecrosis of the jaw - prevention and treatment strategies for oral health professionals. Oral Oncol 49:878, 2013
198. Khan AA, Morrison A, Kendler DL, et al: International task Force on osteonecrosis of the J: Case-based review of osteonecrosis of the jaw (ONJ) and application of the international recommendations for management from the international task Force on ONJ. J Clin Densitom 20:8, 2017
199. Ottesen C, Schiodt M, Gotfredsen K: Efficacy of a high-dose antiresorptive drug holiday to reduce the risk of medication-related osteonecrosis of the jaw (MRONJ): A systematic review. Heliyon 6:e03795, 2020
200. Anastasilakis AD, Polyzos SA, Makras P, et al: Clinical features of 24 patients with rebound-associated vertebral fractures after denosumab discontinuation: Systematic review and additional cases. J Bone Miner Res 32:1291, 2017
201. Cummings SR, Ferrari S, Eastell R, et al: Vertebral fractures after discontinuation of denosumab: A post Hoc analysis of the randomized placebo-controlled FREEDOM trial and its extension. J Bone Miner Res 33:190, 2018
202. Tsourdi E, Langdahl B, Cohen-Solal M, et al: Discontinuation of denosumab therapy for osteoporosis: A systematic review and position statement by ECTS. Bone 11:105, 2017
203. Lorenzo-Pouso AI, Perez-Sayans M, Gonzalez-Palanca S, et al: Biomarkers to predict the onset of biphosphonate-related osteonecrosis of the jaw: A systematic review. Med Oral Patol Oral Cir Bucal 24:e26, 2019
204. Musolino C, Oteri G, Allegra A, et al: Altered microRNA expression profile in the peripheral lymphoid compartment of multiple myeloma patients with bisphosphonate-induced osteonecrosis of the jaw. Ann Hematol 97:1259, 2018
205. Yang R, Tao Y, Wang C, et al: Circulating microRNA Panel as a novel biomarker to Diagnose bisphosphonate-related osteonecrosis of the jaw. Int J Med Sci 15:1694, 2018

206. Durie BG, Katz M, Crowley J: Osteonecrosis of the jaw and bisphosphonates. N Engl J Med 353:99, 2005
207. Hoff AO, Toth BB, Altundag K, et al: Frequency and risk factors associated with osteonecrosis of the jaw in cancer patients treated with intravenous bisphosphonates. J Bone Miner Res 23:826, 2008
208. Dimopoulos MA, Kastritis E, Bamia C, et al: Reduction of osteonecrosis of the jaw (ONJ) after implementation of preventive measures in patients with multiple myeloma treated with zoledronic acid. Ann Oncol 20:117, 2009
209. Yarom N, Shapiro CL, Peterson DE, et al: Medication-related osteonecrosis of the jaw: MASCC/ISOO/ASCO clinical practice guideline. J Clin Oncol 37:2270, 2019
210. Lewiecki EM, Wright NC, Curtis JR, et al: Hip fracture trends in the United States, 2002 to 2015. Osteoporos Int 29:717, 2018
211. Guzon-Illescas O, Perez Fernandez E, Crespi Villarias N, et al: Mortality after osteoporotic hip fracture: Incidence, trends, and associated factors. J Orthop Surg Res 14:203, 2019
212. McCauley LK: Clinical recommendations for prevention of secondary fractures in patients with osteoporosis: Implications for dental care. J Am Dent Assoc 151:311, 2020
213. Moinzadeh AT, Shemesh H, Neirynck NA, et al: Bisphosphonates and their clinical implications in endodontic therapy. Int Endod J 46:391, 2013
214. Gelazius R, Poskevicius L, Sakavicius D, et al: Dental implant placement in patients on bisphosphonate therapy: A systematic review. J Oral Maxillofac Res 9:e2, 2018
215. Holzinger D, Seemann R, Matoni N, et al: Effect of dental implants on bisphosphonate-related osteonecrosis of the jaws. J Oral Maxillofac Surg 72:1937.e1, 2014
216. Granate-Marques A, Polis-Yanes C, Seminario-Amez M, et al: Medication-related osteonecrosis of the jaw associated with implant and regenerative treatments: Systematic review. Med Oral Patol Oral Cir Bucal 24:e195, 2019
217. Stavropoulos A, Bertl K, Pietschmann P, et al: The effect of antiresorptive drugs on implant therapy: Systematic review and meta-analysis. Clin Oral Implants Res 29(Suppl 18):54, 2018
218. Ryu JI, Kim HY, Kwon YD: Is implant surgery a risk factor for osteonecrosis of the jaw in older adult patients with osteoporosis? A national cohort propensity score-matched study. Clin Oral Implants Res 32:437, 2021
219. Giovannacci I, Meleti M, Manfredi M, et al: Medication-related osteonecrosis of the jaw around dental implants: Implant surgery-triggered or implant presence-triggered osteonecrosis? J Craniofac Surg 27:697, 2016
220. Kwon TG, Lee CO, Park JW, et al: Osteonecrosis associated with dental implants in patients undergoing bisphosphonate treatment. Clin Oral Implants Res 25:632, 2014
221. Pogrel MA, Ruggiero SL: Previously successful dental implants can fail when patients commence anti-resorptive therapy-a case series. Int J Oral Maxillofac Surg 47:220, 2018
222. Walton K, Grogan TR, Eshaghzadeh E, et al: Medication related osteonecrosis of the jaw in osteoporotic vs oncologic patients-quantifying radiographic appearance and relationship to clinical findings. Dentomaxillofac Radiol 48:20180128, 2019
223. Coropciuc RG, Grisar K, Aerden T, et al: Medication-related osteonecrosis of the jaw in oncological patients with skeletal metastases: Conservative treatment is effective up to stage 2. Br J Oral Maxillofac Surg 55:787, 2017
224. Soundia A, Hadaya D, Mallya SM, et al: Radiographic predictors of bone exposure in patients with stage 0 medication-related osteonecrosis of the jaws. Oral Surg Oral Med Oral Pathol Oral Radiol 126:537, 2018
225. Varoni EM, Lombardi N, Villa G, et al: Conservative management of medication-related osteonecrosis of the jaws (MRONJ): A retrospective cohort study. Antibiotics (Basel) 10, 2021
226. Ripamonti CI, Cislaghi E, Mariani L, Maniezzo M: Efficacy and safety of medical ozone (O(3)) delivered in oil suspension applications for the treatment of osteonecrosis of the jaw in patients with bone metastases treated with bisphosphonates: Preliminary results of a phase I-II study. Oral Oncol 47:185, 2011
227. Freiberger JJ, Padilla-Burgos R, McGraw T, et al: What is the role of hyperbaric oxygen in the management of bisphosphonate-related osteonecrosis of the jaw: A randomized controlled trial of hyperbaric oxygen as an adjunct to surgery and antibiotics. J Oral Maxillofac Surg 70:1573, 2012
228. Epstein MS, Wicknick FW, Epstein JB, et al: Management of bisphosphonate-associated osteonecrosis: Pentoxifylline and tocopherol in addition to antimicrobial therapy. An initial case series. Oral Surg Oral Med Oral Pathol Oral Radiol Endod 110:593, 2010
229. Morishita K, Yamada SI, Kawakita A, et al: Treatment outcomes of adjunctive teriparatide therapy for medication-related osteonecrosis of the jaw (MRONJ): A multicenter retrospective analysis in Japan. J Orthop Sci 25:1079, 2020
230. Sim IW, Borromeo GL, Tsao C, et al: Teriparatide promotes bone healing in medication-related osteonecrosis of the jaw: A placebo-controlled, randomized trial. J Clin Oncol 38:2971, 2020
231. Carlson ER, Basile JD: The role of surgical resection in the management of bisphosphonate-related osteonecrosis of the jaws. J Oral Maxillofac Surg 67:85, 2009
232. Abu-Id MH, Warnke PH, Gottschalk J, et al: "Bis-phossy jaws" - high and low risk factors for bisphosphonate-induced osteonecrosis of the jaw. J Craniomaxillofac Surg 36:95, 2008
233. Wutzl A, Biedermann E, Wanschitz F, et al: Treatment results of bisphosphonate-related osteonecrosis of the jaws. Head Neck 30:1224, 2008
234. Stanton DC, Balasanian E: Outcome of surgical management of bisphosphonate-related osteonecrosis of the jaws: Review of 33 surgical cases. J Oral Maxillofac Surg 67:943, 2009
235. Wilde F, Heufelder M, Winter K, et al: The role of surgical therapy in the management of intravenous bisphosphonates-related osteonecrosis of the jaw. Oral Surg Oral Med Oral Pathol Oral Radiol Endod 111:153, 2011
236. Adornato MC, Morcos I, Rozanski J: The treatment of bisphosphonate-associated osteonecrosis of the jaws with bone resection and autologous platelet-derived growth factors. J Am Dent Assoc 138:971, 2007
237. Williamson RA: Surgical management of bisphosphonate induced osteonecrosis of the jaws. Int J Oral Maxillofac Surg 39:251, 2010
238. Carlson ER: Management of antiresorptive osteonecrosis of the jaws with primary surgical resection. J Oral Maxillofac Surg 72: 655, 2014
239. Watters AL, Hansen HJ, Williams T, et al: Intravenous bisphosphonate-related osteonecrosis of the jaw: Long-term follow-up of 109 patients. Oral Surg Oral Med Oral Pathol Oral Radiol 115:192, 2013
240. Ristow O, Ruckschloss T, Muller M, et al: Is the conservative non-surgical management of medication-related osteonecrosis of the jaw an appropriate treatment option for early stages? A long-term single-center cohort study. J Craniomaxillofac Surg 47:491, 2019
241. Carlson ER, Schlott BJ: Anti-resorptive osteonecrosis of the jaws: Facts forgotten, questions answered, lessons learned. Oral Maxillofac Surg Clin North Am 26:171, 2014
242. Klingelhoffer C, Zeman F, Meier J, et al: Evaluation of surgical outcome and influencing risk factors in patients with medication-related osteonecrosis of the jaws. J Craniomaxillofac Surg 44:1694, 2016
243. Nisi M, La Ferla F, Karapetsa D, et al: Conservative surgical management of patients with bisphosphonate-related osteonecrosis of the jaws: A series of 120 patients. Br J Oral Maxillofac Surg 54:930, 2016
244. Park H, Copeland C, Henry S, Barbul A: Complex wounds and their management. Surg Clin North Am 90:1181, 2010
245. Giudice A, Barone S, Diodati F, et al: Can surgical management improve resolution of medication-related osteonecrosis of the jaw at early stages? A prospective cohort study. J Oral Maxillofac Surg 78:1986, 2020
246. Rachner TD, Coleman R, Hadji P, Hofbauer LC: Individualized bone-protective management in long-term cancer survivors with bone metastases. J Bone Miner Res 36:1906, 2021

247. Gnant M, Mlineritsch B, Stoeger H, et al: Colorectal cancer study group VA: Zoledronic acid combined with adjuvant endocrine therapy of tamoxifen versus anastrozol plus ovarian function suppression in premenopausal early breast cancer: Final analysis of the Austrian breast and Colorectal cancer study group trial 12. Ann Oncol 26:313, 2015

248. Yang YL, Xiang ZJ, Yang JH, et al: The incidence and relative risk of adverse events in patients treated with bisphosphonate therapy for breast cancer: A systematic review and meta-analysis. Ther Adv Med Oncol 11, 2019 1758835919855235

PART 2 | Oral Surgery and Implantology

Chapter 6 Cysts and Benign Tumors of the Jaws

Eric R. Carlson, Michael Winstead

INTRODUCTION AND OVERVIEW

Cysts and benign tumors of the jaws are intriguing pathologic entities that can be aggressive, destructive and prone to persistence if not properly removed. Their workup must be performed in a precise and methodical fashion to provide effective first-line surgical treatment.

The assignment of a benign versus a malignant designation to a neoplastic pathologic process of the jaws is established based on well accepted and time-honored histologic criteria, such as the presence of absence of necrosis, invasion and mitotic figures, as well as the observed natural history of the pathologic entity, such as the ability of the lesion to recur and metastasize to distant sites. In addition, the adjective aggressive has been routinely applied to malignant neoplasms due to their ability to grow rapidly while indiscriminately and recklessly invading surrounding structures, known as anatomic barriers. Clinical features of skin invasion and histologic features of perineural invasion are, in fact, defining elements of the aggressive character of malignant tumors of the head and neck. By contrast, non-aggressive pathologic processes are more likely to grow slowly while respecting the integrity of surrounding soft tissues including skin, and not threatening the patient's life, thereby connoting a benign designation. Some benign tumors of the jaws might be misconstrued in terms of their true, aggressive biologic behavior due to their benign designation with an underestimation of their destructive and life-threatening character. Under these circumstances, it is possible that conservative therapy for such benign tumors might be non-justifiably offered to patients with observed recurrence of the neoplasm. When benign tumors are removed with the realization of negative histologic margins, their reappearance is generally considered to be unlikely; however, with a cure effectively predicted and most commonly realized. Strictly speaking, when benign jaw tumors reappear following surgical extirpation, they are often incorrectly described as recurrent when, in fact, they truly represent persistent disease due to prior incomplete removal.

Some malignant tumors might be distinctly non-aggressive in terms of their relative indolent biologic behavior and relative slow growth compared to the more typical aggressive malignant tumors. Under these circumstances, unnecessarily radical therapy could be carried out for such malignant tumors with excessive removal of tissue that need not be removed. Therein, the astute clinician recognizes the paradox inherent in the expressions 'aggressive malignant tumors' and 'non-aggressive benign tumors', can distinguish those tumors that do not fall into these pretentious categories and can primarily provide evidence-based tumor surgery with curative intent, and with form and function maintained as important secondary objectives.

CLASSIFICATION OF CYSTS AND BENIGN TUMORS OF THE JAWS

The World Health Organization (WHO) classification of head and neck tumors represents an attempt to achieve uniform nomenclature for international conversation. The uniformity is intended to standardize epidemiological investigation with precise comparisons of lesion incidence worldwide. The classification's fifth edition published in 2022 offers reclassifications and additions that reflect an improved comprehension of the behavioral and morphological range of odontogenic cysts and tumors. The 2022 benign odontogenic tumor classification (***Table 6.1***) reflects numerous changes from its 2005 classification. Of importance is the nomenclature change of the ameloblastomas, now designated as ameloblastoma, conventional; ameloblastoma, unicystic; and ameloblastoma, peripheral/extraosseous. The 2005 designated solid/multicystic ameloblastoma was replaced by ameloblastoma without further elaboration in the 2017 classification, yet some pathologists and surgeons continue to use the solid/multicystic terminology to differentiate the ameloblastoma from the unicystic ameloblastoma. Clearly, differentiation of the conventional ameloblastoma from the unicystic ameloblastoma is paramount due to the different requirements for surgical cure. The ameloblastic fibrodentinoma and the ameloblastic fibro-odontoma do not appear in the 2017 or the 2022 classifications due to being considered developing odontomas, a controversial change that is viewed by some surgeons and pathologists with skepticism.

The 2022 odontogenic cyst classification (***Table 6.2***) represents a renewed inclusion of these entities that were eliminated from the second edition published in 1992 to the third edition published in 2005. Odontogenic cysts, similar in radiographic appearance to some

TABLE 6.1 2022 World Health Organization classification of benign odontogenic tumors.

Ameloblastoma, conventional
Adenoid ameloblastoma
Ameloblastoma, unicystic
Ameloblastoma, extraosseous/peripheral
Metastasizing ameloblastoma
Squamous odontogenic tumor
Calcifying epithelial odontogenic tumor
Adenomatoid odontogenic tumor
Ameloblastic fibroma
Primordial odontogenic tumor
Odontoma
Dentinogenic ghost cell tumor
Odontogenic fibroma
Odontogenic myxoma
Cementoblastoma
Cemento-ossifying fibroma

From: Vered M, Wright JM. Update from the 5th Edition of the World Health Organization Classification of Head and Neck Tumors: Odontogenic and Maxillofacial Bone Tumours. *Head and Neck Pathol* 2022;**16**:63–75.

TABLE 6.2 2022 World Health Organization classification of odontogenic cysts.

Radicular cyst
Inflammatory collateral cyst
Post-surgical ciliated cyst
Dentigerous cyst
Odontogenic keratocyst
Lateral periodontal and botryoid cyst
Gingival cyst
Glandular odontogenic cyst
Calcifying odontogenic cyst
Orthokeratinized odontogenic cyst
Nasopalatine duct cyst

From: Vered M, Wright JM. Update from the 5th Edition of the World Health Organization Classification of Head and Neck Tumors: Odontogenic and Maxillofacial Bone Tumours. *Head and Neck Pathol* 2022;**16**:63–75.

odontogenic tumors that can be cystic, clearly require inclusion in a classification of jaw pathology.

Surgery for benign processes of the jaws is a function of the aggressive versus non-aggressive biologic behavior of the lesion with the proper recognition and execution of required linear and anatomic barrier margin principles. Linear margin principles refer to the quantitative inclusion of uninvolved soft and hard tissues surrounding the tumor. Their inclusion is planned and required due to the understanding that tumors are not seamlessly demarcated entities. Rather, tumors extend beyond their clinical and/or radiographic margins, such that inclusion of seemingly normal tissue increases the likelihood of complete tumor removal. Anatomic barriers are soft and hard tissues that surround a pathologic process and attempt to forestall its growth and infiltration of uninvolved tissues. The quintessential example is a capsule that surrounds some, but not all benign tumors. Unencapsulated benign neoplasms include the ameloblastoma and the pleomorphic adenoma, which are pseudoencapsulated. Some benign tumors produce a capsule while unencapsulated benign tumors result in the host producing a pseudocapsule, both serving as effective anatomic barriers. Malignant tumors do not produce capsules, and are rarely, if ever, pseudoencapsulated. Other anatomic barriers include cortical bone, periosteum, muscle, mucosa, dermis and skin.

PREOPERATIVE COMMON PATHWAYS FOR WORKUP OF JAW PATHOLOGY

Jaw lesions in general, and odontogenic cysts and tumors specifically, collectively represent an abstruse and often elusive group of diagnoses to surgeons not intimately familiar with their clinical and radiographic presentations. It becomes incumbent on clinicians to obtain a comprehensive history to initiate the diagnostic process while also identifying important information to permit establishment of a differential diagnosis. Patients presenting or referred for workup and treatment of jaw pathology must be asked questions regarding the chronicity of the lesion, the rapidity of growth, associated pain or lack thereof, the perception of mobile teeth and neurosensory disturbances, among others. A focused physical examination follows that serves, in part, to assess the anatomic barriers that surround the lesion under investigation. The proximity of the tumor to overlying dermis, palpable cortical perforation by the cyst or tumor, and possible violation of the oral mucosa should be determined and recorded.

Plain film (panoramic radiograph) and sophisticated imaging with computed tomography (CT) or magnetic resonance imaging (MRI) are routinely required for the workup of suspected cysts and benign tumors in preparation for surgical ablation. The clinician's personal preference will dictate the sequence of performing an incisional biopsy of the lesion and obtaining the contrast-enhanced CT scans. A critical review of the CT scan will not only permit refinement of the differential diagnosis, but also enable a more accurate assessment of involved anatomic barriers, while also assessing the pre-test probability of a vascular lesion. Evaluation of CT scans also permits planning of the

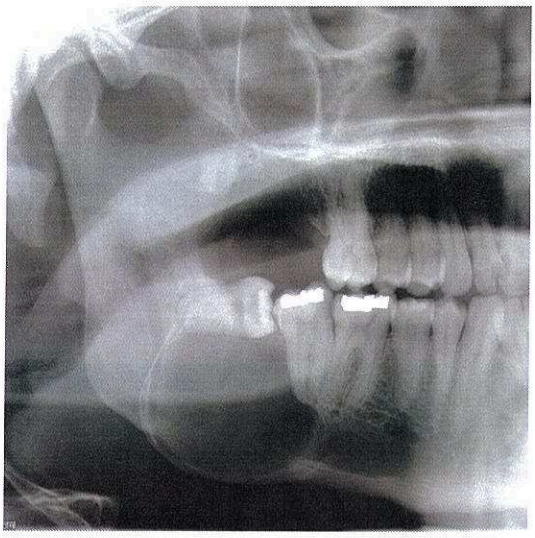

Figure 6.1 Unilocular radiolucency of the right mandible that represents an orthokeratinized odontogenic cyst. The differential diagnosis for this lesion includes entities that are treated identically. The lesion was therefore removed without an incisional biopsy, whereupon the diagnosis was first established following complete removal of the cyst.



Figure 6.2 Multilocular radiolucency of the left mandible. The differential diagnosis for this lesion includes entities that are treated vastly differently. As such, the multilocular radiolucency typically undergoes incisional biopsy before providing definitive therapy to guide the surgeon in terms of specific operative treatment such as segmental resection versus enucleation and curettage. The incisional biopsy of this lesion established a diagnosis of conventional ameloblastoma such that this patient underwent segmental resection with immediate reconstruction of the mandible.

surgical approach to the lesion, specifically regarding an intraoral versus a combined intraoral and extraoral approach to ablation. Finally, the CT appearance of the lesion might persuade the clinician to proceed directly with excision of the lesion without first obtaining an incisional biopsy. For example, the surgeon might be inclined to perform an enucleation and curettage surgery for a unilocular radiolucency of the jaws without first obtaining an incisional biopsy (***Figure 6.1***), while learning of the precise microscopic diagnosis only after providing definitive surgical management of that lesion. By contrast, that surgeon will most commonly obtain an incisional biopsy of a multilocular radiolucency (***Figure 6.2***) to first establish the lesion's microscopic diagnosis prior to performing definitive surgical management of that lesion.

Jaw pathology can present microscopic nuances on incisional biopsies that might create interpretive challenges for pathologists not intimately familiar with these entities, thereby possibly resulting in incomplete or incorrect microscopic diagnoses. Clearly, a failure to properly diagnose the lesion could result in a failure to properly treat the patient's pathology. When an incisional biopsy is submitted for histologic diagnosis therefore, it is valuable for a highly specialized pathologist to review the biopsy and offer a reliable tissue diagnosis to permit the surgeon to perform appropriate surgery. When cases have been diagnosed by those not routinely familiar with odontogenic pathology, for example, a review by an experienced pathologist is essential to this end. Further, a biopsy performed by a referring surgeon in which the tissue diagnosis was offered by a pathologist who does not work with the accepting surgeon is best accessioned and interpreted by a pathologist at the hospital where the surgeon accepting responsibility for the patient will be providing definitive surgical management. Such a review could either confirm the existing microscopic diagnosis of the incisional biopsy or result in a change in diagnosis. The change in the incisional biopsy diagnosis will potentially lead to a change in surgical management.

OPERATIVE MANAGEMENT OF CYSTS AND BENIGN ODONTOGENIC JAW TUMORS

Odontogenic cysts

The odontogenic cysts most commonly encountered in oral and maxillofacial surgery practice include dentigerous cysts and odontogenic keratocysts. In general terms, dentigerous cysts are typically unilocular radiolucencies, while many odontogenic keratocysts are multilocular radiolucencies in the experience of these authors. Certainly, some odontogenic keratocysts are unilocular radiolucent lesions, but dentigerous

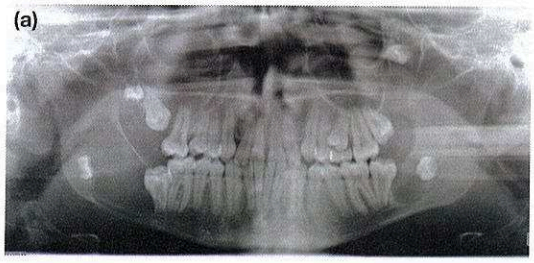

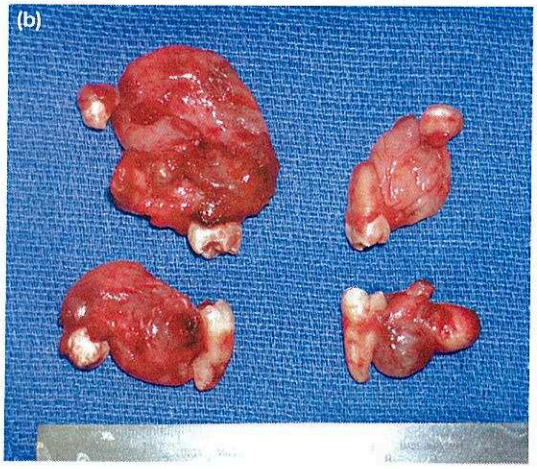

Figure 6.3 Panoramic radiograph **(a)** of an 11-year-old patient with unilocular radiolucencies of the bilateral maxilla and mandible. The multifocal nature of these radiolucencies allows the surgeon to place odontogenic keratocysts high on the differential diagnosis, with a high likelihood of nevoid basal cell carcinoma syndrome. The patient underwent enucleation and curettage of the four lesions **(b)** and four odontogenic keratocysts were confirmed on microscopic evaluation.

cysts do not present as multilocular radiolucencies. As such, a unilocular radiolucency, where the differential diagnosis includes dentigerous cyst and odontogenic keratocyst, will often be definitively surgically managed with enucleation and curettage without performing an incisional biopsy prior to definitive surgical management. Supporting this treatment strategy is the fact that other entities on this differential diagnosis include those that will similarly be definitively managed by enucleation and curettage, such as the central giant cell lesion, ameloblastic fibroma and other benign entities. A multilocular radiolucency, by contrast, requires a different diagnostic strategy. An incisional biopsy is frequently required to establish the microscopic diagnosis prior to executing definitive surgical management, primarily to distinguish the odontogenic keratocyst from the ameloblastoma that can often appear similar radiographically.

- Odontogenic cysts are not managed with attention to linear margin and anatomic barrier principles
- The enucleation procedure should be executed with an attempt to remove the cyst in one piece whenever possible
- Wide surgical access, bright lights and a generally anesthetized patient permit complete removal of the cyst
- The removal of etiologic and associated teeth increases the likelihood of complete removal of the cyst
- The curettage is performed with a sharp Molt curette and may be assisted with adjunctive procedures such as the application of Carnoy's solution, methylene blue or 5-fluorouracil to the resultant cyst cavity in bone

Of great importance in diagnosis and management of the odontogenic keratocyst is detecting the presence of nevoid basal cell carcinoma syndrome. The diagnosis need not include elaborate genetic testing of patients. Rather, recognizing the phenotype and the radiographic features of this syndrome readily permits identification of affected patients, particularly the existence of one or more radiolucent lesions of the jaws (***Figure 6.3***). Under such circumstances, the biopsy of a jaw lesion will confirm the presence of a syndromic odontogenic keratocyst.

Benign odontogenic tumors

Many of the benign odontogenic neoplasms exemplify prototypical principles for benign tumor surgery of the jaws. These include the ameloblastoma, odontogenic myxoma, Pindborg tumor and the radio-opaque cemento-ossifying fibroma. They are true neoplasms that require attention to detail to the principles of bony linear margins and the surrounding anatomic barriers when performing extirpative tumor surgery. These tumors also emphasize the observed paradox of aggressive local, albeit slow, growth.

When a benign neoplastic process exists on the top of the differential diagnosis of a pathologic entity of the jaws, an incisional biopsy is valuable to establish the precise microscopic diagnosis. Its expressed purpose is to permit the surgeon to tailor a surgical procedure in the best interests of cure of the neoplasm, specifically resection versus enucleation and curettage. Finally, the incisional biopsy will rule out the presence of a very rare malignant odontogenic tumor that would require a vastly different surgical treatment plan, specifically regarding the performance of a neck dissection.

The approach to resection of the conventional ameloblastoma, odontogenic myxoma, Pindborg tumor and radio-opaque cemento-ossifying fibroma remains at the discretion of the surgeon, whether transoral or transcutaneous/transoral. In general, the size of the tumor and its superior extent will dictate the specific ablative approach (***Figure 6.4***).

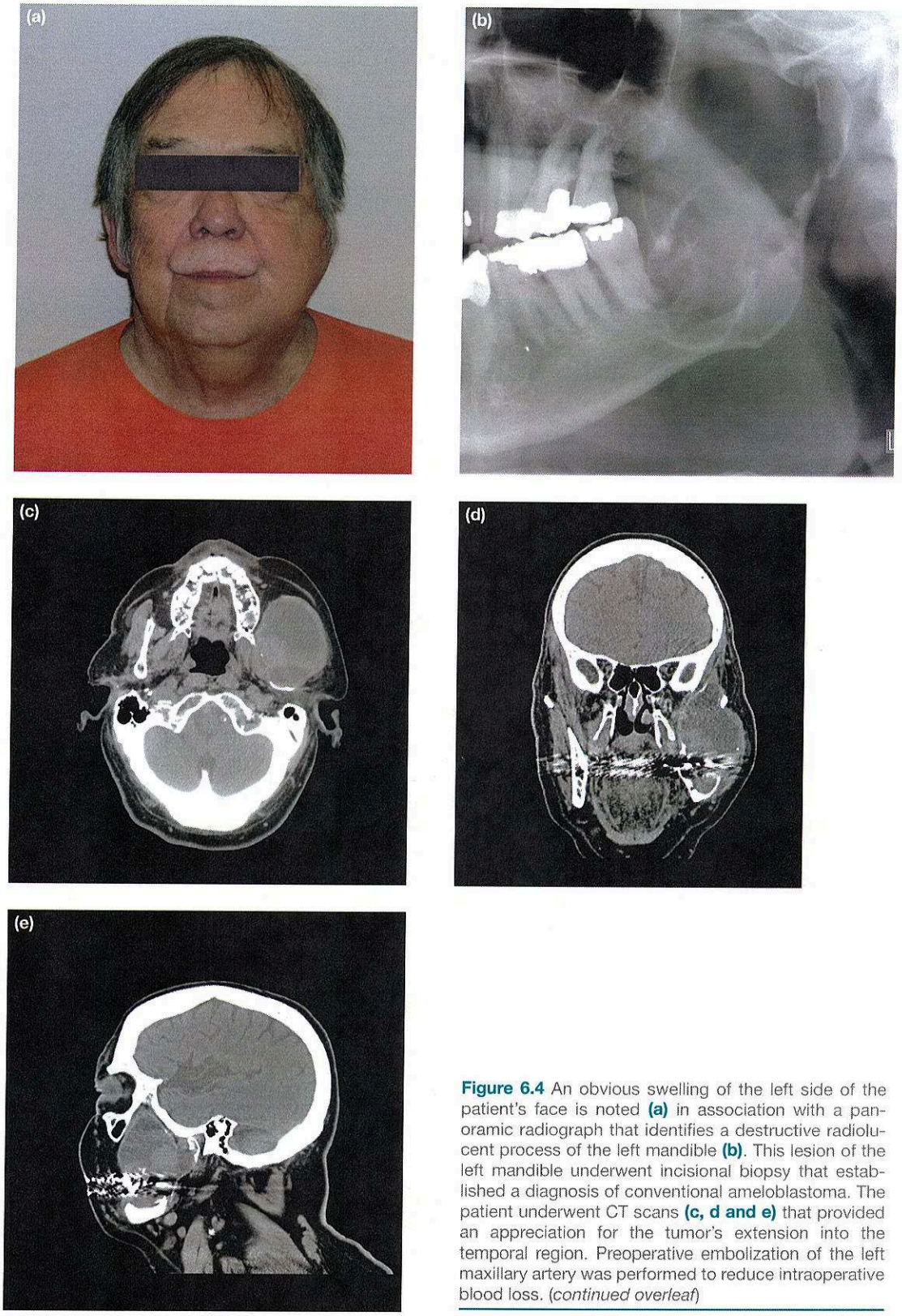

Figure 6.4 An obvious swelling of the left side of the patient's face is noted **(a)** in association with a panoramic radiograph that identifies a destructive radiolucent process of the left mandible **(b)**. This lesion of the left mandible underwent incisional biopsy that established a diagnosis of conventional ameloblastoma. The patient underwent CT scans **(c, d and e)** that provided an appreciation for the tumor's extension into the temporal region. Preoperative embolization of the left maxillary artery was performed to reduce intraoperative blood loss. (*continued overleaf*)

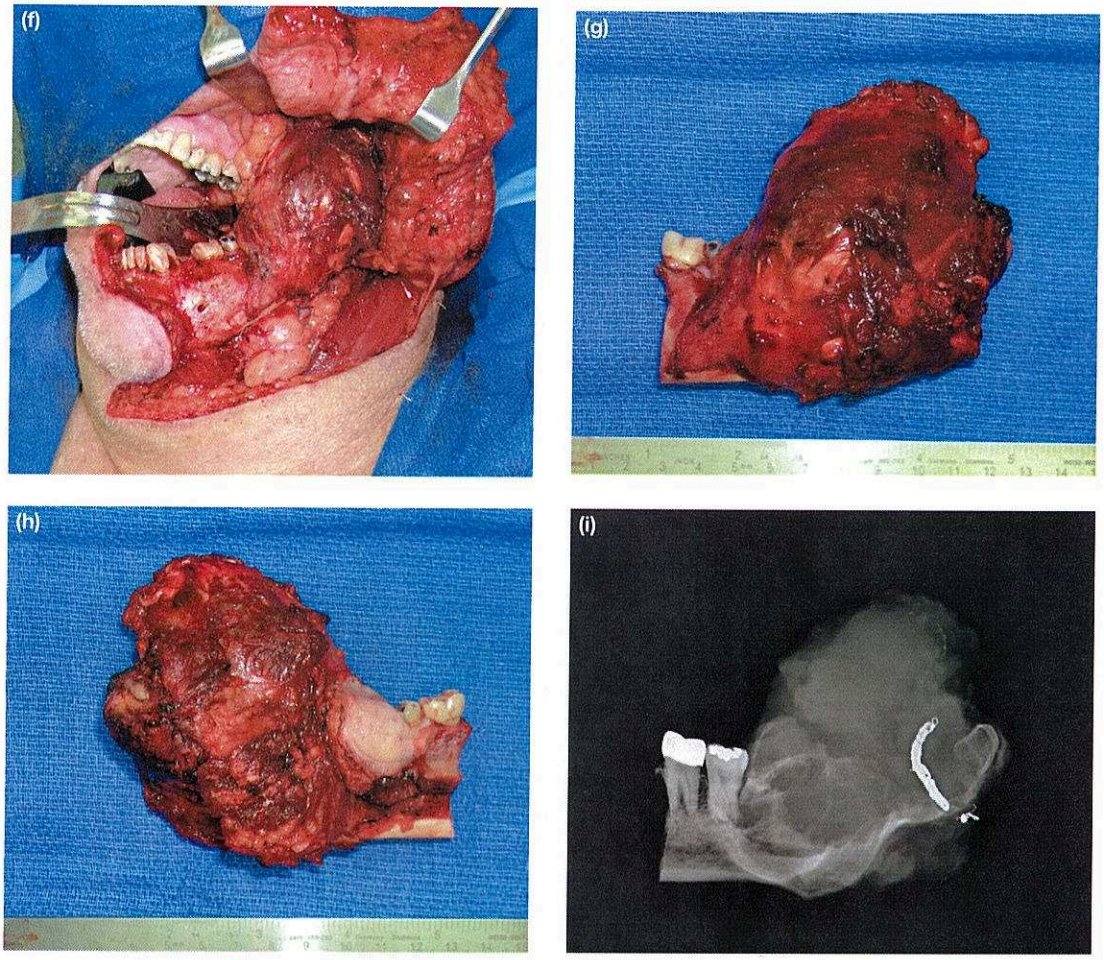

Figure 6.4 (*continued*) The patient required extended access through a lip split approach that provided exceptional access to the region superior to the zygomatic arch **(f)**. The tumor specimen was easily resected **(g and h)** and a specimen radiograph was obtained **(i)**. The patient underwent immediate reconstruction with a fibular osteocutaneous microvascular flap.

Based on the physical examination of the patient and assessment of preoperative CT scans, the surgery begins with a dissection and pre-planned sacrifice of anatomic barriers on the tumor specimen. One centimeter linear bony margins are planned and executed for the conventional ameloblastoma, odontogenic myxoma and Pindborg tumor, while a 5-mm bony margin suffices for the resection of the radio-opaque cemento-ossifying fibroma.

Ideally, a specimen radiograph is obtained to assess the adequacy of the resection in terms of included linear margins. The surgeon will establish a preoperative decision regarding planned reconstruction of the ablative defect of the mandible, with an immediate microvascular bone graft, non-vascularized graft or a reconstruction bone plate and an early delayed bone graft.

The luminal and intraluminal subtypes of the unicystic ameloblastoma, odontoma, ameloblastic fibroma, squamous odontogenic tumor, adenomatoid odontogenic tumor, odontogenic fibroma and the radiolucent cemento-ossifying fibroma are properly managed by enucleation and curettage procedures.

The mural subtype of the unicystic ameloblastoma represents a conundrum in terms of effective treatment. The mural variant of the unicystic ameloblastoma is truly a locally aggressive benign neoplasm of the jaws whose biologic behavior parallels that of the conventional ameloblastoma. As such, the surgeon might opt to manage the mural subtype of the unicystic ameloblastoma with resection with 1-cm bony margins. A definitive diagnosis of the mural subtype of the unicystic ameloblastoma may occasionally be made following an enucleation and curettage surgery, under which

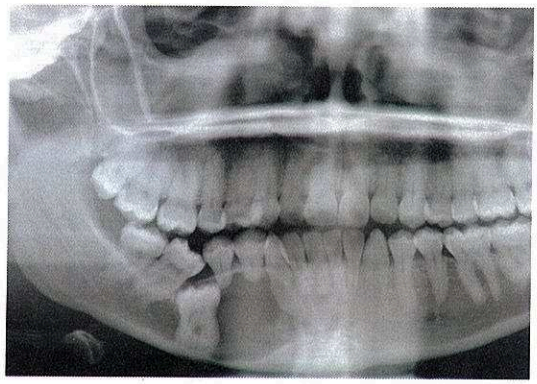

Figure 6.5 Unilocular radiolucent lesion of the right mandible. Primary enucleation and curettage of the lesion resulted in a diagnosis of unicystic ameloblastoma, primarily luminal subtype, but with the initiation of mural disease. Long-term follow-up is required for this diagnosis.

circumstances the surgeon may wish to adopt close clinical and radiographic follow-up rather than committing the patient to a return to the operating room for resection (***Figure 6.5***).

Serial panoramic radiographs should be obtained at regular intervals to promptly diagnose the presence of persistent disease with the subsequent performance of resection. If the diagnosis of a mural subtype of the unicystic ameloblastoma is made based on incisional biopsy, we recommend consideration of primary operative management with resection.

A similar approach to the juvenile ossifying fibroma (JOF) is recommended. The recurrence rate for JOF treated with local excision or curettage is variable such that if this treatment is selected, careful longitudinal follow-up is imperative. Surgical resection with 1-cm bony margins is associated with a lower rate of persistent disease and should be considered as primary surgical therapy.

POSTOPERATIVE FOLLOW-UP OF PATIENTS

The postoperative follow-up of patients with odontogenic cysts and benign tumors depends on the microscopic diagnosis of the lesion, the pathology report's margin status in the case of tumors and the natural history of the lesion. Due to their frequently aggressive biologic behavior, long-term clinical and radiographic follow-up is beneficial to ensure effective cure of patients. This statement is particularly valid for the ameloblastoma; ameloblastoma, mural subtype; odontogenic myxoma; Pindborg tumor; and odontogenic keratocyst.

Top tips and hazards

- Cysts and benign odontogenic tumors of the jaws may present radiographic similarities such that the surgeon should consider incisional biopsy prior to performing definitive surgical management, particularly when multilocular radiolucencies are noted.
- The odontogenic keratocyst stands alone as a cyst that has the propensity for persistent disease at variable times postoperatively. As such, long-term follow-up is required. In fact, the surgeon might wish to follow these patients indefinitely.
- Although typically slow-growing, benign odontogenic tumors of the jaws can be as aggressive, destructive and life-threatening as the more rapidly growing malignant tumors of the jaws. The biologic behavior of benign odontogenic tumors should therefore not be underestimated and curative intent surgery with resection should be planned accordingly.
- Long term, and possibly indefinite, follow-up should occur for patients following resection for conventional ameloblastoma; ameloblastoma, mural subtype; odontogenic myxoma; and Pindborg tumor.
- Some odontogenic tumors in fact represent hamartomas that are approached with enucleation and curettage surgeries with curative intent.
- The resection of a benign odontogenic tumor of the mandible presents the unique opportunity for immediate reconstruction with a microvascular fibular transfer.

FURTHER READING

Carlson ER. Odontogenic cysts and tumors. In: Miloro M (ed). *Peterson's Principles of Oral and Maxillofacial Surgery, 3rd edition*, People's Medical Publishing House; 2012, chapter 29, pp. 625–52.

Carlson ER, Ghali GE. Benign aggressive jaw tumors. In: Har-El G, Day TA, Nathan CAO, Nguyen SA (eds). *Head and Neck Surgery*, Thieme Medical and Scientific Publishers Private Limited; 2013, chapter 24, pp. 263–83.

Carlson ER, Oreadi D, McCoy JM. Nevoid basal cell carcinoma syndrome and the keratocystic odontogenic tumor. *J Oral Maxillofac Surg* 2015;**73**:S77–86.

Kennedy RA. WHO is in and WHO is out of the mouth, salivary glands, and jaws section of the 4th edition of the WHO classification of head and neck tumours. *Br J Oral Maxillofac Surg* 2018;**56**:90–5.

Vered M, Wright JM. Update from the 5th Edition of the World Health Organization Classification of Head and Neck Tumors: Odontogenic and Maxillofacial Bone Tumours. *Head and Neck Pathol* 2022;**16**:63–75.